



Article Original

Clinical Aspects, Surgical Management and Outcome of Chronic Subdural Hematoma at CHU Sylvanus Olympio (Lomé)

Hématomes sous-duraux chroniques : aspects cliniques et prise en charge chirurgicale au CHU Sylvanus Olympio (Lomé)

Komlan Agbéko Doléagbéno¹, Essossinam Kpélao¹, Anthony Katanga Békéti¹, Kodjo Hobli Ahanogbé¹, Abdelkader Moumouni², Komi Egu³

1. : Service de Neurochirurgie CHU Sylvanus Olympio, Lomé – Togo.
2. : Service de Neurochirurgie, CHU Kara, Lomé – Togo.
3. : Polyclinique Internationale Saint Joseph, Lomé – Togo.

Corresponding author :

Komlan A Doléagbéno

E-mail :

achilledoleagbenou@gmail.com

Keywords: chronic subdural hematoma; low- and middle income countries; Togo

Mots-clés : Hématome sous-dural chronique,

ABSTRACT

Objective. Chronic subdural hematoma (CSDH) is common neurosurgical pathology. The authors conducted a study to describe, the epidemiology and the management of CSDH, in a low- and middle-income country. **Materials and methods.** The study was performed at Centre Hospitalier Universitaire Sylvanus Olympio of Lomé (Togo), between november 2017 and december 2018. After approval of the ethics committee of the hospital, patients of any age who presented and were diagnosed with CSDH during the period of the study were included. Variables were collected from patients' files at discharge and follow-up clinic visits. **Results.** Sixty patients, the majority were male (81.8%, 54/66) were enrolled in the study. The sex ratio was 4.5:1. The mean age was 53.91 ± 16.65 years. Prior cranial trauma was identified in 55 patients (83.3%). Limb weakness was the most common presenting symptom (56.1%, 37/66) followed by headache (51.4%, 34/66), and confusion (34.8%, 23/66). All patients underwent surgery. The morbidity was 1.52% and the mortality among surgery was 1.52%. **Conclusion.** Trauma was a common cause of CSDH among younger men patients. Burr-hole surgery with closed drainage was a safe procedure in the treatment of CSDH.

RÉSUMÉ

Introduction. Le but de cette étude était d'évaluer la prise en charge des patients ayant un hématome sous-dural chronique. **Patients et méthodes.** Il s'agit d'une étude descriptive monocentrique de novembre 2017 à décembre 2018, au CHU rétrospective et analytique des dossiers des patients hospitalisés pour un hématome sous-dural chronique, dans le service de Neurochirurgie du CHU SO de Lomé. **Résultats.** Soixante-six patients dont 81,8% étaient des hommes, répondaient aux critères d'inclusion. L'âge moyen de la série était de $53,91 \pm 16,65$ ans. Le traumatisme crânien représentait la principale étiologie (83,3% des cas). Les principaux symptômes à l'admission étaient le déficit de membres (56,1%), suivi des céphalées (51,4%) et de la confusion (34,8%). Tous les patients de la série ont été opérés. La mortalité globale était de 1,52%. **Conclusion.** Le traumatisme crânien est la principale étiologie des hématomes sous-duraux chroniques chez des patients jeunes. La chirurgie constitue le traitement efficace de ces hématomes.

INTRODUCTION

Chronic subdural hematoma (CSDH) is a frequent pathology in neurosurgery [1, 2]. Incidence of CSDH in western literature, increases with age [2,3,4]. Patient demographics differ in Africa, and studies recorded a young population with CSDH [5,6,7]. The treatment of choice for CSDH, is burr-holes with or without drainage[8]. There is a dearth of literature on the causes, clinical presentation, management, and outcomes of CSDH in low- and middle-income countries (LMICs) [8]. Evaluate the causes, clinical presentation, and treatment outcomes of patient who presented with CSDH at Centre Hospitalier Universitaire (CHU) Sylvanus Olympio, a low-income setting, was the objective of this study.

PATIENTS AND METHODS

Study design

Togo is a west african francophone low-income country. The population was 7.6 in habitants in 2017. The Gross Domestic Product (GDP) is \$ 4.76 billion USD in 2017. According to the World Bank, Life expectancy was 60 years old in 2017 [9].

We performed a retrospective and descriptive study at CHU Sylvanus Olympio from November 2017 to December 2018. After approval of the ethics committee of the hospital, we included in the study, patients of any age who presented and were diagnosed with CSDH and operated during this period. Each patient received a non-contrasted computed tomography (CT) scan of head.

Surgery

All patients underwent anesthesia (local or general). The technique (single or double burr-hole or a cranial flap) was chosen according to the surgeon's preference and scan assessment. When membranes exist, they were carefully opened after slight widening of the holes. We proceeded an irrigation of the subdural cavity with normal saline until the returning fluid was nearly clear. A close drainage system (not vacuum) with a tube was left in situ for 48 hours. Prophylactic antibiotics were used for 24-48 hours. Wound infection and recurrence of CSDH were checked in the follow up.

Data collection

The variable studied were demographics, mechanism of injury, symptoms of presentation, admission vitals and neurological exam, imaging findings, type of intervention, and outcomes (death, recurrence, and wound infection). The neurological state of patients was evaluated according to the Markwalder classification [10]. Grade 0: no symptom; Grade 1: moderate symptoms (headache) or slight deficits (reflex asymmetry); Grade 2: confusion or spatio-temporal disorientation with neurological deficits (hemiparesis); Grade 3: stuporous but responsive to painful stimulus; Grade 4: coma without motor response to painful stimulus, decerebrate or decorticate posturing.

Data analysis

Statistical analysis and data processing were performed with the software SPSS version 20. The association between presenting symptoms, SDH mechanism, SDH type with patient age was determined using the Student t-test and ANOVA. Variables found with a p value < 0.05 were considered statistically significant.

RESULTS

Sixty six patients were considered for inclusion in the study. This patient population was composed of 54 men (81.8%), and 12 women (18.2%). The sex ratio was 4.5:1. The mean age of the patient population was 53.91 ± 16.65 years (range 0-82). Prior cranial trauma was identified in 55 patients (83.3%), and troubles of coagulation were identified in 4 patients (6.1%). Limb weakness was the most common presenting symptom (56.1%, 37/66) followed by headache (51.4%, 34/66), and confusion (34.8%, 23/66). The distribution of the signs, type and laterality of SDH on CT scan are reported in Table I. Patients were Grade 2 in 48.5%, according to Markwalder classification (Table II). Patients who reported head trauma were older (54.13 ± 2.40) than those with problematic coagulation (51.25 ± 5.3; Table III). 52 (78.8%) patients underwent surgery in general anesthesia. 14 (21.2) had local anesthesia because of risks associated with general anesthesia given their age and very low level of consciousness. 45 (68.18%) patients had single burr-hole, 20 (30.3%) had double burr-hole, and 1 (1.52%) had craniotomy. 1 (1.52%) patient had superficial wound infection. There was no recurrence of CSDH and no death in the serie.

Table I : Patient demographics

Patient age in yrs, mean (SD)	53.91 (16,65)
Males, n (%)	54 (81.8)
Alcohol consumers, n (%)	42 (63.6)
Smokers, n (%)	9 (13.6)
Presenting Complaint, n (%)	
Headache	34 (51.5)
Confusion	23 (34.8)
Memory loss	6 (9.1)
Convulsions	6 (9.1)
Limb weakness	37 (56.1)
Urinary incontinence	1 (1.5)
GCS score, n (%)	
Mild (score 13-15)	47 (71.2)
Moderate (score 9-12)	17 (25.8)
Severe (score 3-8)	2 (3)
Mechanism	
Head trauma	55 (83.3)
Problematic coagulation	4 (6.1)
No reported cause	7 (10.6)
SDH type, n (%)	
Chronic	40 (60.6)
Subacute	26 (39.4)
SDH laterality	
Right	29 (43.9)
Left	30 (45.5)
Bilateral	7 (10.6)

Table II: Distribution according to the Markwalder Classification

Grade	Symptoms	Number (%)
0	No symptoms	0 (0)
1	Moderate symptoms (cephalalgia) or light deficits (reflex asymmetry)	16 (24.2)
2	Spatio-temporal confusion or disorientation with neurological deficits (hemiparesis)	32 (48.5)
3	Stuporous but responsive to painful stimulus ; severe focal signs (hemiplegia)	13 (19,7)
4	Coma without motor response to painful stimuli ; decerebrate or decorticate posturing	5 (7,6)

Table III : Association of mechanism, presenting symptom, type and presenting symptom of subdural hematoma.

Variable	Mean Age (SD)	p value
Presenting complaint		
Headache	53.88 (2.587)	< 0.001
Confusion	59.48(2.99)	< 0.001
Memory loss	56 (2.61)	0.013
Convulsions	46 (10.2)	0.013
Limb weakness	60.27 (2.38)	< 0.001
Mechanism		
Head trauma	54.13 (2.40)	0.045
Problematic coagulation	51.25 (5.3)	
Type		
Chronic	51.23 (2.85)	0.213
Subacute	58.04 (2.67)	
Laterality		
Right	54.62 (3.11)	0.27
Left	54.97 (2.61)	
Bilateral	46.43 (9.49)	

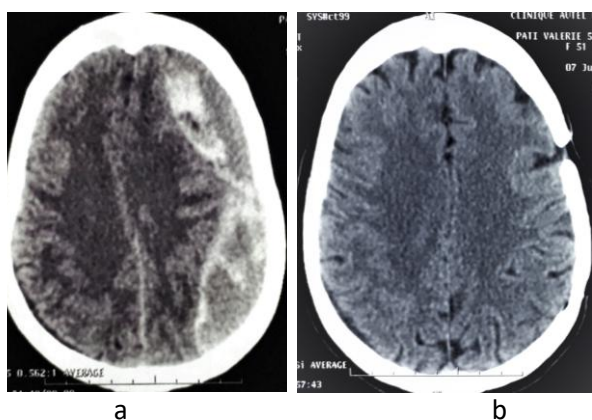


Figure 1 : representative (a) pre operative CT scan and (b) post operative CT scan

DISCUSSION

Chronic subdural hematoma is a frequent pathology in neurosurgery, with an increasing prevalence worldwide [1]. The elderly represent up to 90.9% of those with CSDH [2]. While in High Income Countries (HICs) this occurrence has been attributed to an increase in the size of the elderly population [11, 12], in LMICs there is a high incidence of trauma (Table 4). In our study, the CSDH patients were younger (53.91 ± 16.65 years) than those reported in HICs. Jones S. in UK [1] and Miranda LB in US [13] have documented mean age of 80.6 and 83.8 years. The mean age of CSDH in sub-saharan Africa is less than 60 years [6, 8, 14, 15, 16]. Our finding may be attributable to a young average age of the general population in Togo as well as a higher incidence of

cranial trauma, that affect younger patients [6,7,8,14,15,16,17,18].

We found a preponderance of males, with a ratio of 4.5:1, which is higher than the ratio of 2.5:1 noted by Kitya [8] in Uganda, and the 1.7:1 found by Miranda LB [13], in US. The predominance of males in our study and in other studies, is probably due to the fact that men are more exposed to trauma than females [19].

Limb weakness was the most common presenting symptom (56.1%, 37/66) followed by headache (51.4%, 34/66), and confusion (34.8%, 23/66), in our study. Kitya [8] Uganda, Dakurah [6] in Ghana, Mezue [7] in Nigeria, found headache as the most common presenting symptoms followed by confusion. In US, headache was less common in the elderly [20].

Treatment of CSDH using burr holes with or without drainage has persisted as the therapy of choice. In a few patients, craniotomy is warranted [8]. In our study 45 (68.18%) patients had single burr-hole, 20 (30.3%) had double burr-hole, and 1 (1.52%) had craniotomy. Single burr-hole remains the predominant technique according to the majority of sub-saharan publications (Table 5). There was no recurrence of CSDH and no death in our serie. In Ghana, Dakurah et al. [6] reported recurrence and death rates of 2.1% and 2.1% respectively. In Benin, Hode et al. [16], reported no recurrence and death rates of 3%. The mortality in our serie is lower than others sub-saharan authors (Table 4) and some authors in LMICs [4, 21, 22]. In studies from HICs such as the US and Sweden, the recurrence rate has varied widely, between 3% and 37% [23, 24, 25]. Compressive pneumocephalus inducing post-operative line shift is predictive of unilateral CSDH recurrence [26]. In the study, there was no pneumocephalus on CT scan control for patients with unilateral CSDH (Figures 1, 2).

In our study, we report good patient outcomes associated after operative management of CSDH. Only 1 (1.52%) patient had superficial wound infection. This low infection rate was similar with the publications from Uganda, Nigeria and Greece [5, 8, 27].

Study limitations

There are several limitations to our study. The data were collected from patient files completed upon patient discharge, some data were missing. Our sample size was limited to only 66 patients, thus making it difficult to determine whether our findings over- or under estimate the true frequencies of patient presentation, injury mechanisms, and outcomes. In Togo, and in LMICs, neurosurgeons represent a small minority of physicians, and advanced diagnostic imaging modalities such as CT and diagnostic centers are only available in urban areas [28, 29]. Additionally given that, the clinical presentation of CSDH mimic other medical conditions such as stroke, dementia, which are also prevalent in the same age group [30, 31, 32, 33, 34]. As a result of this broad and unspecific clinical presentation, and the lack of available diagnostic imaging and neurosurgeons, many patients may not be referred to the neurosurgical ward, which can further delay surgery.

Conflict of interests

Authors declare that they have no conflict of interest.

CONCLUSION

This study characterizes the causes, clinical presentation, and the treatment outcomes of patient who presented with CSDH at CHU Sylvanus Olympio. Trauma was a common cause of CSDH among younger men patients. Burr-hole surgery with closed drainage was a safe procedure in the treatment of CSDH.

Author contributions

Komlan A Doléagbéno : substantial contributions to conception and design, acquisition of data, drafting the article and revising it critically for important intellectual content ; Final approval of the version to be published.

Essossinam Kpélao : substantial contributions to conception and design, acquisition of data, final approval of the version to be published.

Anthony K Békéti : drafting the article and revising it critically for important intellectual content ; final approval of the version to be published.

Kodjo H Ahanogbé : final approval of the version to be published.

Abdelkader Moumouni : final approval of the version to be published.

Komi Egu : final approval of the version to be published.

All authors read and agreed to the final version of this manuscript and equally contributed to its content and to the management.

REFERENCES

- 1- Jones S, Kafetz K: A prospective study of chronic subdural haematomas in elderly patients. *Age Ageing*.1999 Oct;28(6):519-21
- 2- Kerabe S, Ozawa T, Watanabe T, Atoa T: Efficacy and safety of post-operative early mobilization for chronic subdural haematoma in elderly patients. *Acta Neurochir (Wien)*. 2010;152:1171–1174
- 3- Ducruet AF, Grobelny BT, Zacharia BE, Hickman ZL, DeRosa PL, Anderson K, et al. The surgical management of chronic subdural hematoma. *Neurosurg Rev*. 2012;35(2):155-69; discussion 69.
- 4- Gelabert-Gonzalez M, Iglesias-Pais M, Garcia-Allut A, Martinez-Rumbo R. Chronic subdural haematoma: surgical treatment and outcome in 1000 cases. *Clinical neurology and neurosurgery*.2005 Apr;107(3):223-9
- 5- Adeolu AA, Rabiou TB, Adeleye AO: Post-operative day two versus day seven mobilization after burr-hole drainage of subacute and chronic subdural haematoma in Nigerians. *Br J Neurosurg*.2012 Oct ;26(5):743–746
- 6- Dakurah T, Idrissu M, Wepeba G, Nuamah I: Chronic subdural haematoma: review of 96 cases attending the Korle Bu, Teaching Hospital, Accra. *West Afr J Med*.2005 Oct-Dec ;24(4):283–286
- 7- Mezue WC, Ohaebgulam SC, Chikani MC, Erechukwu AU: Changing trends in chronic subdural haematoma in Nigeria. *Afr J Med Med Sci*.2011 Dec;40(4):373–376
- 8- Kitya D, Punchak M, Abdelgadir J, Obiga O, Harborne D, Haglund MM: Causes, clinical presentation, management, and outcomes of chronic subdural hematoma at Mbarara Regional Referral Hospital. *Neurosurg Focus*.2018 Oct ;45(4):E7.

- 9- World Bank. Togo: Country at a glance: <http://www.worldbank.org/en/country/togo>; 2019 [march 21, 2019].
- 10- Markwalder TM. Chronic subdural haematoma: A review. *Journal of neurosurgery*.1981 May;54(5):637-45.
- 11- Contini S: Surgery in developing countries: why and how to meet surgical needs worldwide. *Acta Biomed*.2007;78(1):4–5
- 12- Idro R: Acquired brain injury in children in Sub-Saharan Africa, in Musisi S, Jacobson S (eds): *Brain Degeneration and Dementia in Sub-Saharan Africa*. New York: Springer Science.2015;183–199
- 13- Miranda LB, Braxton E, Hobbs J, Quigley MR: Chronic subdural hematoma in the elderly: not a benign disease. *J Neurosurg*.2011 Jan ;(1):72–76
- 14- Djientcheu V. P. EA, Yamgoue T., Tchaleu B., Ze Minkande J. Surgical treatment and outcome of 195 cases of non acute subdural haematoma at the yaoundé central hospital: the need for landmarked burr holes. *AJNS*. 2011;30(2):19-27
- 15- Mwanyombet Ompounga L., Ada Loembe F.C., Loembe P.M. Traitement des hématomes sousduraux chroniques à Libreville (Gabon) : revue de 102 cas. *AJNS*. 2011;30(2):28-38
- 16- Hode L, Quenum K, Fatigba O.H, Fanou L, Lansdale G.S.H. Treatment and Outcome of Chronic Subdural Hematoma in Sub-Saharan Africa and the Country of Benin. *IrJNS*. 2015;1(2):31-35
- 17- Bankole O B YAS, Kanu O O, Ukponmwan E N M N, Arigbabu S O. chronic subdural haematoma: clinical presentation, surgical treatment and outcome at the lagos university teaching hospital. *AJNS*. 2011;30(1):10-7
- 18- Hima-Maiga A. SY, Ndoye N., Ba M.C., Diallo M., Badiane S.B. Chronic subdural hematomas in Dakar: clinical, diagnostic, therapeutic and evolving features in the age of the scanner (a propos of 88 cases). *Mali Med*. 2008;23(4):11-6
- 19- Baechli H NA, Bucher HC, Gratzl O. Demographics and prevalent risk factors of chronic subdural haematoma: results of a large singlecenter cohort study. *Neurosurg Rev*. 2004;27(4):263–6
- 20- Fogelholm R, Heiskanen O, Waltimo O: Chronic subdural hematoma in adults. Influence of patient's age on symptoms, signs, and thickness of hematoma. *J Neurosurg*.1975 Jan;42(1):43–46
- 21- Nayil K, Ramzan A, Sajad A, Zahoor S, Wani A, Nizami F, et al. Subdural hematomas: an analysis of 1181 Kashmiri patients. *World Neurosurg*. 2012;77(1):103-10.
- 22- Sousa EB, Brandao LF, Tavares CB, Borges IB, Neto NG, Kessler IM. Epidemiological characteristics of 778 patients who underwent surgical drainage of chronic subdural hematomas in Brasilia, Brazil. *BMC surgery*. 2013;13:5.
- 23- Koliass AG, Chari A, Santarius T, Hutchinson PJ: Chronic subdural haematoma: modern management and emerging therapies. *Nat Rev Neurol*.2014 Oct;10(10):570–578
- 24- Mellergrad P, Wisten O: Operations and re-operations for chronic subdural haematoma during a 25 year period in a well-defined population. *Acta Neurochir*.1996;138:708–713
- 25- Traynelis VC: Chronic subdural hematoma in the elderly. *Clin Geriatr Med*.1991 Aug ;7(3):583–598
- 26- Dudoit T, Labeyrie PE, Deryckere S, Emery E, Gaberel T. Is systematic post-operative CT scan indicated after chronic subdural hematoma surgery? A case–control study. *Acta Neurochir (Wien)*.2016 Jul ;158 (7), 1241-1246
- 27- Rovlias A, Theodoropoulos S, Papoutsakis D: Chronic subdural hematoma: surgical management and outcome in

- 986 cases: a classification and regression tree approach. *Surg Neurol Int.*2015 Jul 30 ;6:127
- 28- Akbar A: Myelography in spinal disorders—experience of 1400 cases. *J Pak Med Assoc.*2004 ;54:604–609
- 29- Park BE: Surgical treatment of degenerative lumbar spine disease in rural Sub-Saharan Africa: a retrospective study of 450 cases and its future implications. *World Neurosurg.*2016 Mar;87:417–421
- 30- Abdulla AJ, Pearce VR: Reversible akinetic-rigid syndrome due to bilateral subdural haematomas. *Age Ageing.*1999;28:582–583
- 31- Adhiyaman V, Asghar M, Ganeshram KN, Bhowmick BK: Chronic subdural haematoma in the elderly. *Postgrad Med J.*2002 Feb;78(916):71–75
- 32- Kudo H, Kuwamura K, Izawa I, Sawa H, Tamaki N: Chronic subdural hematoma in elderly people: present status on Awaji Island and epidemiological prospect. *Neurol Med Chir (Tokyo).*1992 Apr ;32(4):207–209
- 33- Potter JF, Fruin AH: Chronic subdural hematoma—the “great imitator”. *Geriatrics.* 1977 ;32:61–66
- 34- Sunada I, Inoue T, Tamura K, Akano Y, Fu Y: Parkinsonism due to chronic subdural hematoma. *Neurol Med Chir (Tokyo).*1996;36:99–101