



Cas Clinique

Difficulties in Histological Diagnosis of a Case of Lymphoma Secondary to Acute Renal Failure

Difficulties in histological diagnosis of a case of lymphoma secondary to acute renal failure in a nephrology department in sub-saharan africa

Guei Monlet Cyr^{1*}, Konan Serge Didier², N'Dah Kouamé Justin³, Lagou Delphine Amelie¹, Diopoh Sery Patrick², Asseke Fréjus², Choho Carole¹, Yao Kouamé Hubert², Ackoundou-N'Guessan Kan Clément¹, Gnionsahé Dazé Apollinaire¹.

RÉSUMÉ

Nephrology is a new discipline in Sub-Saharan Africa. For a better management of many nephropathies, histological data are necessary in terms of diagnosis, therapy as well as prognosis. However, performing the renal needle biopsy (RNB) is very challenging. We report inadequacy of human, material and financial resources for histological data collection through the case of a 21-year-old patient with lymphoma secondary to acute renal failure.

ABSTRACT

Nephrology is a new discipline in Sub-Saharan Africa. For a better management of many nephropathies, histological data are necessary in terms of diagnosis, therapy as well as prognosis. However, performing the renal needle biopsy (RNB) is very challenging. We report inadequacy of human, material and financial resources for histological data collection through the case of a 21-year-old patient with lymphoma secondary to acute renal failure.

¹Nephrology Department, University Teaching Hospital of Yopougon, BP 632, Abidjan 21, Côte d'Ivoire

² Nephrology Department, University Teaching Hospital of Yopougon, Km 1, boulevard de Marseille, BP V 206, Abidjan, Côte d'Ivoire

³ Department of Anatomy and Pathological Cytology, University Teaching Hospital of Cocody, 01 BPV 13 Abidjan 01, Côte d'Ivoire

Correspondent: Dr Guei Monlet Cyr,
Email : cyrguei@yahoo.fr

Key words: Renal histology, Lymphoma, Renal failure, Anatomical pathologist

Key words: Renal histology, Lymphoma, Renal failure, Anatomical pathologist

INTRODUCTION

Nephrology is a relatively new discipline in Africa, particularly in Black African countries. The diagnosis of some renal diseases, such as the renal complications of non-Hodgkin's malignant lymphoma (NHML), is histological. In our countries, there is, on the one hand, the general pauperization of the populations which often curbs the performance of para-clinical tests including renal needle biopsy (RNB) and leads to nearly a shortage of RNB equipment (biopsy needles and/or gun). On the other hand, there is lack of anatomical pathologists, especially those who specialized in kidney pathology. The authors report difficulties in obtaining histological data in a case of lymphoma secondary to acute renal failure (ARF).

CLINICAL CASE

This is a 21-year-old patient hospitalized for the treatment of ARF.

His history goes back to approximately 4 weeks, prior to his admission for a bilateral lower back pain not suggestive of renal colic and associated with asthenia. He

went to a clinic where the physical examination results were virtually normal with stable hemodynamics and apyrexia. The complete blood count (CBC) revealed anemia of 10.5g/dl, and the other parameters of the CBC were normal. Serum creatinine was 20mg/l (177µmol/l). The thick blood smear was negative. However, the patient received anti-malarial treatment with injectable artemether for three days on an outpatient basis without success. The clinical presentation worsened with the appearance of a discrete bilateral parotid swelling and lower limb edema. During a 2nd consultation, he benefited from a symptomatic treatment with oral furosemide. The aftermath was marked by the occurrence of an altered general health (AGH). He attended another health facility where the biology examination revealed a C reactive protein (CRP) of 22mg/l and a serum creatinine of 80mg/l (708µmol/l). The patient was then referred to the nephrology department for the management of his renal failure. The interview did not reveal any particular past medical history or nephrotoxic drug intake.

The physical examination identified a bilateral lower back pain without lumbar contact, bilateral edema of the lower extremities (ELE), fine crackling in the left lung field, and painless febrile cervical, submandibular and inguinal polyadenopathy. There was neither hepatomegaly nor splenomegaly.

Biologically, renal function was impaired with urea of 1.98g/l (33.66 mmol/l) and creatinine of 88mg/l (779 μ mol/l). The blood ionogram and transaminases were normal. There was anemia of inflammation with hemoglobin of 9.5g/dl. The other parameters of the complete blood count were normal. The CRP was 24mg/l. The LDH were elevated to 1284 IU/l. HIV, and Hepatitis B, C, and Syphilis tests were negative. The urine strip test showed a cross for the presence of protein without leucocytes, red blood cells or nitrites. 24-hour proteinuria was 0.24 grams.

The chest x-ray showed left perihilar alveolar opacities. There was no mediastinal adenopathy.

On ultrasound, the kidneys had a normal size with multiple hypoechoic nodules formations and no dilatation of the pyelocaliceal cavities. The liver had a normal size, and was heterogeneous with multiple disseminated hypoechoic nodules formations. There was neither ascites nor deep lymphadenopathy.

Non-Burkitt lymphoma (NHML) was strongly suspected during the cervical ganglion cytopuncture. The inguinal lymph node biopsy detected a small-cell NHML. (Figure 1).

The kidney and liver needle biopsies could not be performed due to lack of biopsy needles during the patient's hospitalization period.

The diagnosis of diffuse small-cell NHML (with kidney and liver involvement) associated with pneumonitis was made. There was a favorable outcome of pneumonia with antibiotic therapy. Given the renal failure severity, he underwent a total of six hemodialysis sessions.

Immunohistochemistry could not be performed and the patient died before starting the chemotherapy, after one week of hospitalization.

DISCUSSION

The clinical manifestations of renal lymphomas are predominated by the classic triad of: lumbar mass, lower back pain and hematuria. This triad was associated with an altered general health (AGH) or fever. Our patient presented only with AGH and lower back pain. There was no hematuria.

Renal involvement is either secondary to hematogenous diffusion in the context of multi-organ involvement or due to contiguous retroperitoneal lymphadenopathy. In rare cases, renal involvement may be primitive as reported by some authors [1,2]. The diagnostic criteria for primary renal lymphoma consist of: [3]

- Initial presentation in the form of unexplained ARF
- Increase in the kidneys size
- The diagnosis is confirmed by the histological assessment of the kidneys
- Absence of extra-renal lymphomatous involvement
- Regression of symptomatology after treatment.

In our patient case, we suspected a kidney involvement secondary to hematogenous diffusion in this context of multi-organ involvement (kidney involvement with multiple hypoechoic nodules formations, ARF and liver involvement with multiple hypoechoic nodules formations). Kidney involvement by contiguity was ruled out in our patient case in the absence of retro-peritoneal adenopathy. Moreover, his case did not meet the diagnostic criteria for primary renal lymphoma, since the kidneys did not increase in size and he presented with extra-renal lymphomatous involvement (cervical and inguinal lymphadenopathies).

The involvement may also be secondary to an immunological mechanism.

The diagnosis of renal lymphoma is histological. In our patient case, the kidney biopsy could not be performed owing to stock-out of biopsy needles. However, in view of the cervical ganglion cytopuncture strongly suspected of non-Hodgkin's malignant lymphoma and the histological diagnosis of lymphoma made for the inguinal lymph node biopsy, we made the final diagnosis of NHML with probably extra-ganglionic localizations, based on the ultrasound images of the liver and kidneys and the ARF.

Indeed, the pharmacy of the University Teaching Hospital (UTH) of Yopougon does not have any renal biopsy needle, or single-use renal biopsy gun yet. We have been performing percutaneous renal biopsy since 2010 using a biopsy gun to which we fix the needles. This gun is graciously made available to the nephrology department by a physician of that department. The city pharmacies also have neither needles nor kidney biopsy guns. This is probably due to the low demand; there are only two public departments of Nephrology in Côte d'Ivoire. The supply of needles has been made by a private supplier engaging in informal-sector activities with often stock-out periods.

The minimum cost of performing an RNB is 167,000 CFA francs (i.e. € 254.6 and US \$ 310). It includes the purchase of the biopsy needle, asepsis equipment, local anesthesia, analgesics, the costs of 2-day hospitalization in the absence of complications and the costs of the anatomical pathology examination. This cost amounts to € 243.22 (US \$ 299) in France [4] and US \$ 1968 (€ 1600) in the United States of America [5], where health insurance has been provided by private insurance companies. This cost of € 254.6 is high for our populations, the majority of whom are poor without health insurance coverage. This constitutes, when the biopsy equipment is available, an additional obstacle to performing RNB and thus to obtaining a histological diagnosis that is so necessary for the management of several nephropathies.

Besides the lack of material and financial resources, there is a shortage of pathologists (see Table 1). In Côte d'Ivoire, there is only one pathologist who specialized in renal pathology for a population of 24.4 million inhabitants [6]. The majority of French-speaking African countries do not have pathologists who specialized in renal pathology. In 2017, France had 1618 pathologists of all specialties [7]

In terms of treatment, there are several modalities: chemotherapy, surgery or radiotherapy [8]. With regard to chemotherapy, it is actually polychemotherapy, mostly the CHOP type which is increasingly associated with rituximab. It gives better results as compared to conventional chemotherapy [9].

CONCLUSION

Histology proves essential in terms of diagnosis, therapy and prognosis in several kidney diseases. However, when performing renal needle biopsy (RNB), we encounter several barriers in our developing countries, particularly in Africa. These barriers can be summed up in the lack of human, material and financial resources.

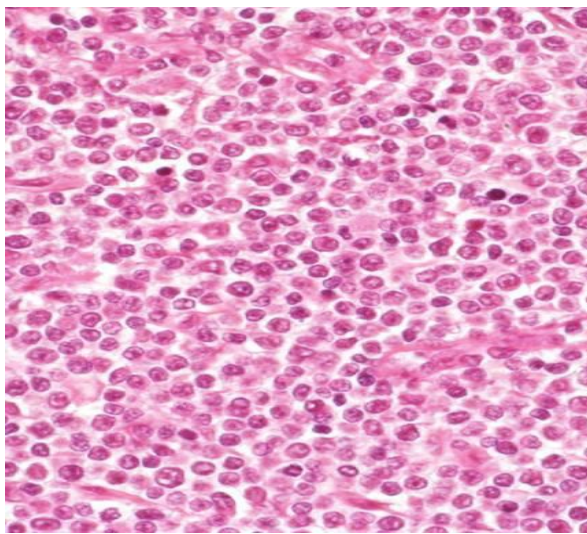


Figure 1: Non-Hodgkin's lymphoma (HE x 25): diffuse cell proliferation consisting of lymphocytes, centrocytes and lymphoblasts with cytonuclear and mitotic atypias.

REFERENCES

- [1] Rhizlane B. Primary renal non-Hodgkin lymphoma: Unusual diagnosis for renal mass. *Indian Journal of Cancer* 2011; 48(2): 255-256.
- [2] Geetha N. Primary renal lymphoma-a case report. Site *ecancer*2014, 8:466 DOI: 10.3332/ecancer.2014.466
- [3] Charasse C. Lymphome rénal primitif révélé par une insuffisance rénale oligo-anurique : une observation. *Rev Med Interne* 1994;15(1):138.
- [4] Bourgoin H, P. Gatault, P. Mutinelli, J. Grassin, J. Halimi, M. Buchler. La ponction biopsie rénale : étude pharmaco-économique. *Le Pharmacien Hospitalier et Clinicien* 2012, vol 47, supl 1 S83.
- [5] Chesney DS, Brouhard BH, Cunningham RJ. Safety and cost effectiveness of pediatric percutaneous renal biopsy. *PediatrNephrol.* 1996 Aug;10(4):493-5.
- [6] Société Ivoirienne de Pathologie. XIV èmes Journées de la Division d'Afrique Francophone de l'Académie Internationale de Pathologie (DAF-AIP) et la II èmes Journées de la Société Ivoirienne de Pathologie (SIPath) du 28 Février au 2 Mars 2018. <https://www.sipath-ci.org> (consulté le 20/03/2018)
- [7] La démographie des médecins. TABLEAU 1. EFFECTIFS DES MÉDECINS par spécialité, mode d'exercice, sexe et tranche d'âge. www.data.drees.sante.gouv.fr (consulté le 18/03/2018)
- [8] Olusanya AA. Primary renal non hodgkins lymphoma presenting with acute renal failure. *J Natl Med Assoc* 2003;95:220-4.
- [9] Diskin CJ. Acute renal failure due to a primary renal B-cell lymphoma. *Am J Kidney Dis* 2007;50(5):885-9.
- [10] Populations et Sociétés, 2017 n° 547. <https://www.ined.fr> (consulté le 12/03/2018)

Table 1: Distribution of pathologists in the French-speaking Africa Division of the International Academy of Pathology [6]

Countries	Number of pathologists	Pathologists specialized in renal pathology	Population in mid-2017 (in million)
Cote d'Ivoire	11	1	24.4
Senegal	10	1	15.8
Burkina Faso	7	0	19.6
Benin	6	0	11.2
Central African Republic	6	1	4.7
Mali	4	0	18.9
Guinea (Conakry)	4	0	11.5
Mauritania	3	0	4.4
Niger	3	0	20,6
Togo	3	0	7,8
Chad	2	0	14,9
NB: Population in mid-2017 [10]			