



Research article

Acanthiomeatal Baseline for Temporal Bone CT-Scan in Children: A Study of Eye Lens Doses and Image Quality

Évaluation du plan acanthioméatal dans le scanner des rochers de l'enfant : une étude comparative des doses au cristallin et de la qualité de l'image

Nwatsock JF^{1,2}, Guersen J¹, Diné PE^{1,3}, Marie Biard¹, Jean-Marc Garcier^{1,4}, Louis Boyer^{1,4}

ABSTRACT

Background. Routine CT-scan of temporal bone with flexed neck (RFN) is often associated with exposure of eye lenses and excessive irradiation of this sensitive organ, with a high-risk of radiation-induced opacities, particularly in children. Acanthiomeatal baseline (AMB), a feasible alternative, remains insufficiently evaluated in living patients. We prospectively assessed the CT-scan radiation doses to the eye lens and the quality of images of temporal bone by comparing the AMB and the RFN. **Methods.** Using a 64-slice scanner with parameters as low as reasonably achievable, we performed helical acquisitions with 35 patients in RFN group and 52 patients in AMB group, over a period of 56 months, by 1:2 dispatching principle depending of the sequence and the compliance of each child. The lens dose was measured using thermoluminescent dosimeters and 3 radiologists blinded to patient group evaluated image quality. *P*-values <0.05 were considered significant for all statistical tests performed. **Results.** Patients of RFN group were aged 3.0 ± 2.8 (1-5) years versus 7.8 ± 4.4 (3-12) years in AMB group, with respectively 48.57% versus 0% of direct lens exposure ($p=0.03$). The mean CTDI_{vol} and DLP were respectively 33.5 ± 7.2 mGy and 213 ± 48.9 mGy.cm, without difference between the groups ($p=0.79$ and 0.28). The lens dose was lower in AMB group: reduction of 78.7%, from 11.25 mGy in RFN to 2.4 mGy in AMB ($p=0.04$). The distance between the scanned volume and the lens was significantly higher in the AMB group ($p=0.04$) and was strongly correlated to the lens dose ($R=-0.99$; $p<0.001$). Concerning the secondary endpoint, the images obtained from both baselines were of equal quality ($p=0.484$) and useful for diagnosis. **Conclusion.** The proposed AMB protocol for temporal bone CT-scan on children can be easily used, with a 1/4.7 decrease of irradiation dose to the eye lenses and equal interpretability of images. We recommend thus this baseline for all compliant children.

RÉSUMÉ

Introduction. Le scanner des rochers en routine (RFN) s'accompagne d'une exposition et d'une irradiation excessive des cristallins avec un risque de cataracte radio-induite surtout chez l'enfant. Le plan acanthioméatal (AMB), une alternative étudiée sur des modèles anthropomorphiques et cadavériques, reste insuffisamment étudié chez le vivant. Nous avons évalué prospectivement l'irradiation du cristallin et la qualité d'images en comparant AMB et RFN. **Matériels et méthodes.** Sur un scanner 64 barrettes avec des paramètres les plus bas possibles, nous avons réalisé 35 TDM des rochers d'enfants en RFN et 52 en AMB, sur une période de 56 mois, selon un principe de répartition 1:2 dépendant de l'ordre d'arrivée et de la compliance des patients. Les doses délivrées au cristallin étaient mesurées par thermoluminescence et la qualité d'images évaluée par 3 radiologues ignorant le plan d'acquisition de l'examen. Les valeurs de $p<0,05$ étaient considérées comme significatives pour tous les tests statistiques effectués. **Résultats.** Les patients en RFN étaient âgés de $3,0 \pm 2,8$ (1-5) contre $7,8 \pm 4,4$ (3-12) ans pour le groupe AMB, avec une exposition directe des cristallins dans 48,57% contre 0% respectivement ($p=0,03$). Les moyennes de CTDI_{vol} et DLP étaient respectivement de $33,5 \pm 7,2$ mGy et $213 \pm 48,9$ mGy.cm, sans différence entre les 2 groupes ($p=0,79$ et $0,28$). La dose au cristallin était plus faible dans le groupe AMB avec une réduction de 78,7%, de 11,25 mGy en RFN à 2,40 mGy en AMB ($p=0,04$). La distance entre le volume scanné et le cristallin était plus élevée dans le groupe AMB ($p=0,04$) et était fortement corrélée à la dose au cristallin ($R=-0,99$; $p<0,001$). Les images issues des 2 plans d'acquisition étaient d'égale qualité ($p=0,844$) et utilisables pour le diagnostic radiologique. **Conclusion.** L'AMB proposé pour la TDM des rochers est de réalisation facile chez l'enfant et permet de réduire l'irradiation des cristallins d'un ratio 1/4,7 (près de 80%) sans détérioration de la qualité des images. Nous recommandons donc l'usage de l'AMB pour tous les enfants compliant.

¹. Medical Imaging Department, Clermont-Ferrand University Teaching Hospital, 63000 Clermont-Ferrand, France

². Department of Medical Imaging and Radiation Oncology, Faculty of Medicine and Biomedical Sciences of the University of Yaounde I, Yaounde, Cameroon

³. Blaise Pascal - Clermont 2 University, Clermont-Ferrand, France

⁴. ISIT, UMR 6284 CNRS, Auvergne-Clermont 1 University, Clermont-Ferrand, France

Auteur correspondant :

Dr Joseph-François Nwatsock

PO Box: 13386 Yaounde

Tél : (+237) 699836068

Email: jfnwatsock@yahoo.ca

Keywords: Lens dosimetry, temporal bone CT-scan, paediatrics' radiology, acanthiomeatal baseline

Mots-clés : Dosimétrie aux cristallins, Scanner des rochers, Radiologie pédiatrique, Plan acanthioméatal

INTRODUCTION

Computed tomography scan (CT-scan) is a useful technique in evaluation of petrous bone structures in patients with suspected anatomical lesions that may be linked to hearing impairment, trauma and other pathologies such as cholesteatoma. This imaging technique provides an analysis of the external ear, ossicles and osseous labyrinth [1, 2, 3, 4]. The repeated use of this CT-scan in the paediatric population is often limited, due to a direct exposure of eye lens by the primary beam during acquisition on the standard orbitomeatal baseline protocol [5, 6].

The lens is one of the most sensitive organs to radiation, especially in children. The risk of radiation-induced cataract is well documented. Recent studies demonstrated that lens radiation-induced cataract could appear when absorbed doses reach 500mGy. However, experimental studies suggest that opacity formation begins for doses as low as 100mGy [7, 8, 9]. In order to investigate temporal bone pathology, modified acquisition baselines have been proposed, such as the acanthiomeatal baseline (AMB), in order to avoid direct exposure of the lens to the radiation beam. With the same technical parameters, this approach may significantly reduce the dose delivered to the eye lens [10, 11].

In the literature, some teams have evaluated radiation dose in CT-scan with adult and paediatric anthropomorphic phantoms or cadaveric heads with controversial conclusions [10, 11, 12]. In this prospective comparative trial, we aimed to compare in children two temporal bone CT-scan baselines, the flexed neck routine baseline (RFN) with slices parallel to the orbitomeatal line and the extended neck baseline with slices parallel to the acanthiomeatal line (AMB), with radiation dose to the eye lens as primary endpoint and image quality as secondary endpoint.

PATIENTS AND METHODS

Study design, patients and ethics

We carried out a non-randomized prospective and comparative study of 87 paediatric patients investigated for petrous pathology over a period of 56 months (from April 2013 to December 2017) in the paediatric radiology department of Estaing Clermont-Ferrand Hospital. We explored patients under the age of 15, seen in the Ear, Nose and Throat (ENT) units for various clinical conditions and referred for CT-scan imaging of the temporal bone. Patients were consecutively enrolled into two groups, RFN and AMB, in a 1:2 allocation ratio depending of the sequence of arrival and the compliance of each child. The parents of each child provided consent for their children to be included in this study. They were provided with details of the study and encouraged to support the preparation of the child to achieve maximum compliance and to reduce anxiety without sedation. The Department of clinical Research of our institution provided ethical clearance for this study.

CT-scan protocol

All the CT-scans were performed on a 64-slice scanner (GE CT Discovery 750 HD of General Electric® Medical Systems, Milwaukee, Wisconsin, USA) by using helical scanning mode. The parameters were as low as reasonably achievable for paediatric population: 100-110 kV, 180 mAs, 0.6 mm collimation and a 0.53 pitch. The acquisition field of view was 18 cm, with bone high-resolution filter and a 512 x 512 matrix. For image acquisition, two different scanning baselines were used:

RFN group (Control): for this group, the axial images of 35 patients were acquired with the flexed neck, so that the acquisition volume passes above the eye lens (Figure 1A).

AMB group (Intervention): in this group, the neck of 52 patients was extended on a 30° angle from orbitomeatal line, to have the scanning baseline parallel to the acanthiomeatal line. In this position, the scanned volume passed beneath the eye lens (Figure 1B).

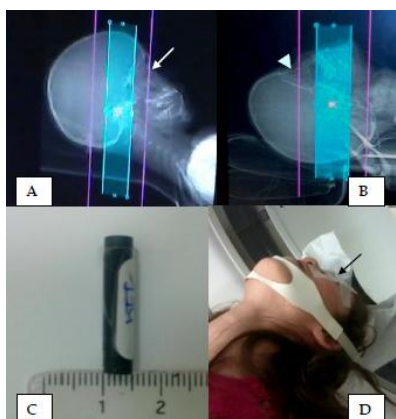


Figure 1: Scanning baselines and thermoluminescent dosimeter

A Acquisition volume and coverage on RFN protocol: images are acquired with the neck flexed, so that the acquisition volume passes above the eye lens (white arrow).

B: Acquisition volume and coverage on AMB: the neck of the patient is extended on at least a 20° angle from orbitomeatal line to have the scanning baseline parallel to the acanthiomeatal line.

C: Thermoluminescent dosimeter: the TLD thickness corresponded to the lens thickness (5 mm).

D: The TLD (black arrow) was positioned just on the closed left upper eyelid.

Dosimetry

In all cases, the radiation dose delivered to the lens was directly measured using thermoluminescent dosimeters (TLD) whose thickness corresponded to the lens diameter [13] (5mm; Figure 1C) and that were placed just on the closed upper eyelid (Figure 1D). To study the global radiation delivered during acquisition, we analysed the dosimetric reports including Dose-length product (DLP) and volumic CT-scan dose index (CTDI_{vol}).

Reading of CT-scan and evaluation of image quality

Image quality was evaluated on the basis of artifact and interpretability analysis as described by other authors [10, 11, 12, 14]. A preliminary session for evaluation of image quality was conducted from April to December 2013 with the images of the first 10 patients (4 in RFN and 6 in AMB). For each patient, multiplanar images of petrous bone at different anatomic levels were displayed on a two-screen "Advantage Workstation"[®]. The axial, coronal and maximum intensity projection (MIP) reformatted images were performed with a 0.6 mm section thickness and 0.3 mm interval. The reading window was 3000-4000 UH with a level of 500-1000 UH. Three radiologists experienced in reading temporal bone CT-scan images rated artifact and image interpretability. They were blinded to the acquisition baseline used. The AMB as well as RFN images were displayed on either the left or right monitor, unknown to the observers who reviewed the images at the same time. The artifact rating was assigned on a three-point scale: 0 = severe artifact; 1 = moderate; 2 = none. Diagnostic image quality was also rated on a three-point scale as described in other literature studies [3]; 1 = less than standard image quality; 2 = equivalent to standard image quality; 3 = optimal.

The second viewing session was conducted with the images of the five last patients included in each group (the 5 last on RFN group and the 5 last on AMB group). The principle, methodology and observers were the same as during the preliminary evaluation. This session aimed to consolidate the evaluation of images. At the end of this evaluation, the total interpretation scores were thus rated from 1 to 5 as follow: 1-2 = low quality (non-interpretable image); 3-4 = standard image quality; 5 = optimal image quality.

Statistical analyses

Using a precoded datasheet, the data were entered into a Microsoft Excel[®] 2011 worksheet and analysed by a prewritten syntax file using the software «Statistical Package for Social Sciences (IBM[®] SPSS 21.0 for MacBook[®])». Scores from the reviewers were pooled for analysis. Image quality scores between the RFN and the AMB protocols were compared using Mann-Whitney *U* test. Associations between variables were determined using Chi-square and Fischer exact tests. Correlations between eye lens doses, distance to the scanned volume and CTDI_{vol} were tested using linear regression equation and Pearson's correlation coefficient. For all statistical analyses, a *p*-value less than 0.05 was considered to indicate a statistically significant difference.

RESULTS

Characteristics of the patients

Eighty-seven children aged from 1 to 12 years were included in the final sample with 35 in RFN group and 52 in AMB group. Six children initially admitted for AMB were not compliant with the neck extension and their CT-scans were then performed with RFN baseline. The age of children included in AMB group was higher than those in the RFN group, with mean ages of 7.8±4.4 (3-12) versus 3.0±2.8 (1-5) years respectively (Table 1). The male to female ratio was 1.5/1. The temporal bone CT-scan was indicated for hearing impairment investigation for 60.92% of cases (53 patients), chronic or persistent otitis media for 19,54% (17 cases) and for control after treatment (cholesteatoma or cochlear implant) for 19,54% (17 cases).

Table I: Analysis of the impact of the acquisition baselines on variables

Variables	Overall sample	Flexed neck	AMB	<i>p</i> values
Mean age (m ± sd years)	6.17 ± 4.4	3.0 ± 2.8	7.8 ± 4.4	0.24
Median age (M [interquartile interval])	5 [3 – 11]	3 [1 – 5]	8 [4 – 11]	
Female to male Sex-ratio	0.67	0	1	0.06
Lenses exposure frequency (%)	19.54	48.57	0.0	0.03
Distance to scanned volume (mm)	24 [18 – 35]	10 [0 – 22]	35 [31 – 36]	0.04
Eye lens delivered dose (m ± sd mGy)	6.8 ± 7.1	11.25 ± 8.4	2.4 ± 1.5	0.04
CTDI _{vol} (m ± sd mGy)	33.5 ± 7.5	32.8 ± 7.7	34.4 ± 7.9	0.79
DLP (m ± sd mGy.cm)	213.0 ± 48.9	191.3 ± 46.9	227.5 ± 48.5	0.28

*Analysis of the impact of the acquisition baselines on variables showed that the eye lens dose and the lenses exposure frequency were significantly lower on AMB group, with a higher distance between lens and the last slice of the scanned volume

Eye lens exposure and radiation dosimetry

Seventeen patients included (19,54%) had a direct exposure of the eye lenses to radiation beam, and all these patients were in the RFN group, representing an exposure frequency of 48.57% in this group. The distance between the lenses and the last slice of scanned volume was significantly higher in the AMB group (*p*=0.04, Table 1).

The general CTDI_{vol} and DLP means in our sample were respectively 33.5±7.2 mGy and 213 ± 48.9 mGy.cm. There was no significant difference in CTDI_{vol} and DLP values between the two groups (*p*=0.79 and 0.28; Table 1). The mean dose delivered to the eye lens was significantly lower in AMB group, with a reduction of 78.7% of the doses delivered (*p* = 0.04; Table 1).

Correlations between delivered dose, $CTDI_{vol}$ and distance to scanned volume

There was a strong correlation between the delivered lens doses and the distance to scanned volume. The lens dose regressed when this distance increased ($R^2=0.98$;

$p<0.001$, Figure 2). But the lens dose did not correlate well with $CTDI_{vol}$ when lenses were not exposed to the radiation beam, as well as when there was direct exposition.

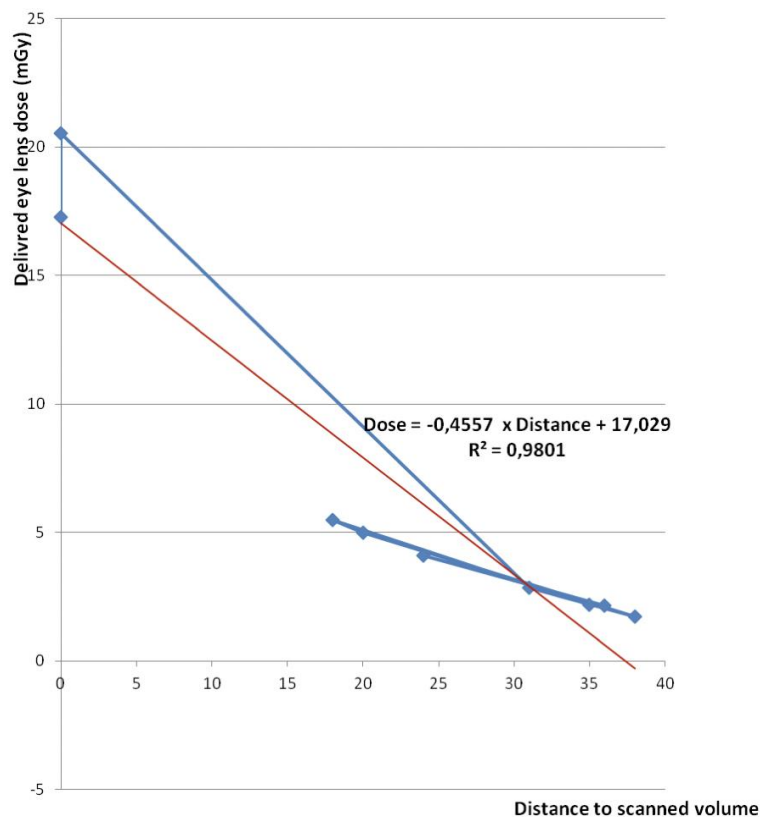


Figure 2: Correlation of the delivered lens doses with the distance to scanned volume

The delivered dose was very well related to the distance to scanned volume. Lens dose values regressed with distance ($R^2 = 0.98$, $p<0.001$)

Quality and interpretability of images

As shown in Figure 3, images obtained with AMB CT-scan appeared to be comparable to those obtained with the RFN baseline protocol, with regards to diagnostic quality and interpretability. AMB images were rated as diagnostically adequate, clearly demonstrating the anatomy and lesions in the explored temporal bones.

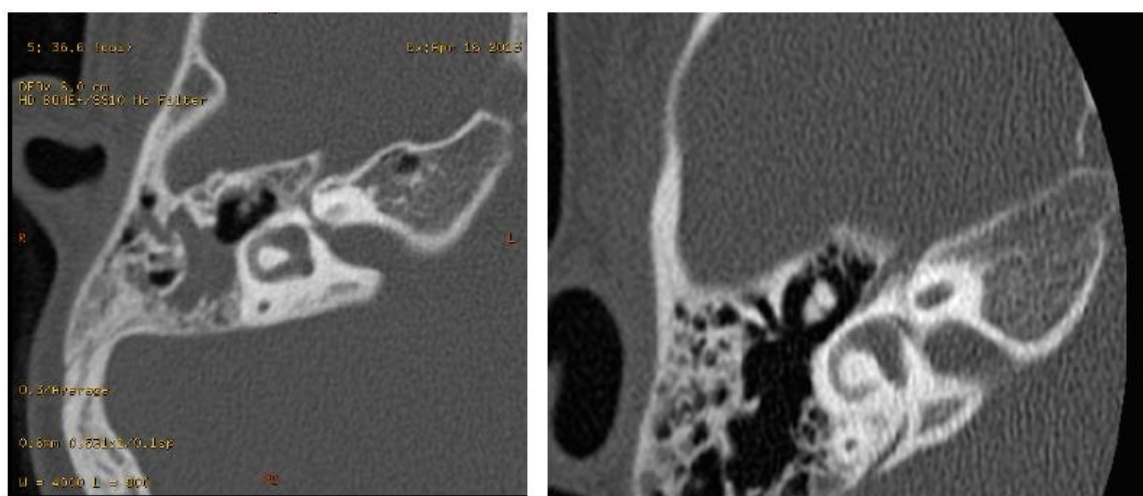

Figure 3: Axial reformatted images of petrous bone issued from AMB and RFN protocol.

The images acquired from AMB (A) as well as those from RFN acquisition (B) were reformatted in coronal and lateral semi-circular canal baseline. These images demonstrated the anatomy and lesions, and they were well used for imaging diagnosis.

The differences in artifact rating and diagnostic quality were not statistically significant (Table 2). These images were used appropriately for imaging diagnosis.

Table II: Evaluation of image interpretability

Evaluated parameters*	RFN score (9 patients)	AMB score (11 patients)	Mann-Whitney U value	p-value
Artefact /2	1,44 (13/9)	1,36 (125/11)	47,5	0.912
Image quality /3	2,44 (22/9)	2,45 (27/11)	49,5	0.484
Total scale /5	3,88	3,81		

*The observers rated artifact and diagnostic quality by blinded method (RFN=Routine Flexed neck group; AMB=Acanthiomeatal baseline group). Rates were compared using Mann-Whitney U test

DISCUSSION

In this prospective non-randomised controlled trial, we aimed to assess the merits and feasibility of the acanthiomeatal baseline in temporal bone CT-scan in children compared to routine baseline performed with flexed neck, by evaluating the eye lenses radiation doses as primary endpoint, and the interpretability of images as secondary endpoint. Our methodology raises one main comment: it is now recognized that the MOSFET (Metal Oxide Semiconductor Field Effect Transistor) dosimetric systems are best suited for measurements of doses to organs located on the surface [15]. But this detector type is not very suitable for measurements in CT-scan and is further advised for radiation therapy. The TLD was thus the first-choice dosimeter, especially for this study on eye lens [16] and has been also used in other studies.

We observed a lower frequency of direct exposure to the lenses, with a corresponding reduction of 78.7% in lenses doses and a similar image quality. The lens radiation exposure during temporal bone CT scan, and other procedures like dacryocystoplasty, has been reported in several studies [6, 7, 10, 11, 17, 18], which have highlighted the associated risks, mainly in paediatric populations. But some controversies remain. Michel et al [9], in a 2012 study, reported that the direct exposure of eye lenses is often unavoidable, especially in cases of repeated examinations. In their series, higher parameters were used (120 kv, 200 mAs), and the mean value of dose delivered to the lens per CT varied from 53±9 mGy to 71±27 mGy. These high levels of the irradiation doses have shown the importance of carefully estimation of the benefit-risk ratio of each CT-scan examination, and the need of optimization of procedures. Niu et al [10] in another study in 2012 achieved the measurements of radiation doses to the lenses with TLD on exsomatized cadaveric head, using different temporal bone CT-scanning baselines, and they reported a reduction of 74.3% of the lens organ dose, from 40.17 to 10.33 mGy when the scanning baseline was modified to be parallel to the AMB. In our department, the routine protocol for temporal bone scanning has been optimised, with low parameters and the flexion of the neck to avoid the children's lenses. Unfortunately, even in this position the exposure of lenses remains common as shown in our series. Even when the eye is avoided, it remains too close to the scanned volume with greater radiation by the scattered rays. Our results demonstrate that the distance between the lens and scanned volume is optimal on AMB, with a significant lens dose reduction. These

results corroborate thus, in living patients, the findings of Niu et al. Moreover, the lens organ doses delivered in our department are lower than those found in most reported studies.

In AMB group, the mean age of the children was higher than in the RFN group. Indeed, children older than age 3 were more compliant to the neck extension than younger kids. In these younger patients, the neck flexion was better accepted than extension. Concerning the global radiation delivered during the acquisition, the means DLP and CTDI_{vol} in our sample were in line with the recommendations of the International Commission of Radiological Protection (ICRP) in paediatrics [19], with a CTDI_{vol} ≤ 50±5 mGy and DLP ≤ 200±20 mGy.cm. Jaffe et al [20] demonstrated that there are some correlations between organ dose and CTDI_{vol}. They used then the linear regression equation to obviate complex modelling programs in orders to determine the absorbed foetal dose during multidetector CT-scan examinations. In our study, the low correlation is explained by the fact that our examinations were performed with the same constant parameters.

The images acquired with AMB were not more noised than those from RFN. Multiplanar reformations were thus performed as clearly as in RFN acquisition. Torizuka et al [21] also evaluated the irradiation dose to the lens and the visualization of temporal bone structures by scanning along two baselines: as in our series, they did not find any difference between images acquired from orbitomeatal baseline and those acquired from a baseline parallel to the hard palate.

CONCLUSION

This study showed that the use of AMB for temporal bone CT-scan in children is very well achievable, especially for patients older than 3 years, and is associated with a decrease of irradiation dose to the eye lens by a 1/4.7 factor (78.7%), without any deterioration in the image quality. The measured lens dose in this situation is strongly linked to the distance between the lens and the scanned volume that is optimal in AMB. These findings strengthen the pertinence of using the AMB. Therefore, we recommend the systematic use of AMB, with the RFN protocol used only when children are not compliant with the neck extension.

Disclosure of interest

The authors do not declare any conflict of interest in relation with this article.

Acknowledgements

We warmly thank Mr Bruno Pereira of the Clinical research department of Clermont-Ferrand CHU (France) for his statistical assistance, Dr Lawrence Mbuagbaw Chinedu of St Joseph's Healthcare Hamilton (Canada) for the reading of the manuscript, and the parents of patients who participated in this study.

The authors wish to thank Mr. Francis Nyuyki and Mrs. Arabella Tambe for logistic assistance during data collection, and the patients who participated in this study.

Authors' contributions

JFN conceived the study and participated in image reading and rating, data collection, analysis and drafting of the manuscript.

JG participated in data collection and dosimetric analysis.

PED participated in data collection.

MB participated in image reading and rating.

JMG participated in study design and correction of drafts.

LB participated in proof-reading and correction of the final draft.

All authors approved the final version of the manuscript.

RÉFÉRENCES

- Martin C, Darrouzet V, et al. Indications et techniques d'imagerie de l'oreille et du rocher. Recommandations de la SFORL. SF ORL-CIREOL. Fr ORL 2008;94:361-5.
- Prades JM, Elmaleh-Berges M, Chatard S, Veyret C, Martin C, Richard C. Computed tomography of the normal and pathologic temporal bone. *Morphologie* 2011;95(311):159-69.
- Chatard-Baptiste S, Martin C, Pouget JF, Veyret C. Surdités brusques : intérêt de l'imagerie, à propos d'une étude prospective de 37 cas. *J Radiol* 2009;90:1823-35.
- Motah M, Sende-Ngonde C, Beyiha G, Belley-Priso E, Malongte-Nguemgne C, Gonsu-Fotsin J et al. Prise en charge des traumatismes crâniens isolés à l'Hôpital Général de Douala. *Health Sci Dis* 2011;12(3):1-6.
- Tweed JJ, Davies ML, Faulkner K, et al. Patient dose and associated risk due to radiological investigation of the internal auditory meatus. *Br J Radiol* 1991;64:447-51
- Siddle KJ, Sim LH, Case CC. Radiation doses to the lens of the eye during computerised tomography of the orbit: a comparison of four modern computerised tomography units. *Australas Radiol* 1990;34:323-5.
- ICRP. Radiopathology of skin and eye and radiation risk. ICRP Publication 85. *Ann ICRP* 2000;30(2).
- Ainsbury EA, Bouffler SD, Dorr W, Graf J, Muirhead CR, Edwards AA et al. Radiation cataractogenesis: a review of recent studies. *Radiat Res* 2009;172:1-9.
- Michel M, Jacob S, Roger G, Pelosse B, Laurier D, Ducou Le Pointe H, Bernier MO. Eye lens radiation exposure and repeated head CT scans: A problem to keep in mind. *Eur J Radiol* 2012;81(8):1896-1900.
- Niu Y, Wang Z, Liu Y, Liu Z, Yao V. Radiation dose to the lens using different temporal bone CT scanning protocols. *Am J Neuroradiol* 2010; 31:226-9.
- Kulski A, Serhal M, Nguye KV, Rehel JL, Rebibo G, Lescure R et al. Comparaison dose versus qualité d'image des scanners hélicoïdaux 16 barrettes des rochers de l'adulte. *J Radiol* 2005;86(10):1381.
- Peet DJ, Pryor MD. Evaluation of a MOSFET radiation sensor for the measurement of entrance surface dose in diagnostic radiology. *Br J Radiol* 1999;72:562-8.
- Allouch C, Touzeau O, Kopito R, Borderie V, Laroche L. Étude biométrique du cristallin par échographie A et Orbscan. *J Fr Ophtalmol* 2005;28(9):925-32.
- Hu H, He DH, Foley WD, Fox SH. Four multidetector-row helical CT: Image quality and volume coverage speed. *Radiology* 2000;215(1):55-62.
- Dong SL, Chu TC, Lan GY, Wu TH, Lin YC, Lee JS. Characterisation of high-sensitivity "Metal Oxide Semiconductor Field Effect Transistor" dosimeters system and LiF:Mg,Cu,P Thermoluminescence dosimeters for use in diagnostic radiology. *Appl Radiat Isot* 2002;57(6):883-91.
- Fujii K, Aoyama T, Yamauchi-Kawaura C, Koyama S, Yamauchi M, Ko S et al. Radiation dose evaluation in 64-slice CT examinations with adult and paediatric anthropomorphic phantoms. *Br J Radiol* 2009;82:1010-8.
- Ilgit ET, Meric N, Bor D, Öznur I, Konus Ö, Isik S. Lens of eye: radiation dose in balloon dacryocystoplasty. *Radiology* 2002;217(1):54-7.
- Meriç N, Yüce UR, Ilgit ET. Radiation dose in balloon dacryocystoplasty: a study using Rando phantoms and thermoluminescent dosimetry. *Diagn Interv Radiol* 2005;11(3):166-9.
- ICRP, 2007. The 2007 Recommendations of the International Commission on Radiological Protection. ICRP Publication 103. *Ann ICRP* 2007;37(2-4):1-332.
- Jaffe TA, Neville AM, Anderson-Evans C, Long S, Lowry C, Yoshizumi TT et al. Early first trimester foetal dose estimation method in a multivendor study of 16- and 64-MDCT scanners and low-dose imaging protocols. *Am J Roentgenol* 2009;193(4):1019-24.
- Torizuka T, Hayakawa K, Satoh Y, Tanaka F, Saitoh H, Okuno Y et al. High-resolution CT of the temporal bone: a modified baseline. *Radiology* 1992;184:109-11.