

Case report

Avascular Femoral Segmental Necrosis After Intramedullary Nailing

Nécrose Avasculaire Segmentaire Fémorale Après Enclouage Centromédullaire

Tsiagadigui JG¹, Essomba NE¹, Moby H¹, Bayiha A², Arabo S², Don A Zok³

¹ Faculty of Medicine and Pharmaceutical Sciences, Douala

² Douala Laquintinie hospital

³ Yaoundé General Hospital

Corresponding author: Emmanuel Noël Essomba

Faculté de Médecine et Sciences Pharmaceutiques. Université de Douala Cameroun

B.P : 15253 Douala

Tél : +237 77551808 / Fax : 237 33 42 4459

Email : noeesso@yahoo.fr

ABSTRACT

The authors report a case of necrosis occurred after diaphyseal femoral intramedullary nailing. The objective of the study was to describe the difficulties of interpretation of radiographs that could suggest a postoperative osteitis. The patient, aged 14 and heterozygous sickle (AS) had received nailing open fire following a highway accident that resulted in a fracture of the femur. Post pictures - operative cortical lysis had suspected osteitis. The absence of clinical signs and scintigraphic images were allowed to establish the diagnosis of diaphyseal aseptic necrosis. The removal of the nail without further treatment was followed by a rapid normalization of radiographic images.

Key words: avascular necrosis, intramedullary nail, bone scintigraphy.

RÉSUMÉ

Les auteurs rapportent un cas de nécrose diaphysaire fémorale survenue après enclouage centromédullaire. L'objectif du travail était de décrire les difficultés d'interprétation de radiographies qui auraient pu laisser penser à une ostéite post opératoire. La patiente, âgée de 14 ans et drépanocytaire hétérozygote (AS) avait bénéficié d'un enclouage à foyer ouvert à la suite d'un accident de la voie publique ayant entraîné une fracture du fémur. Les images post - opératoires de lyse corticale avaient fait suspecter une ostéite. L'absence de signes cliniques et les images de scintigraphie avaient permis d'établir le diagnostic de nécrose diaphysaire aseptique. L'ablation du clou sans autre traitement avait été suivie d'une normalisation rapide des images radiographiques.

Mots clés : Nécrose avasculaire, clou centromédullaire, scintigraphie osseuse.

INTRODUCTION

A 14th years female patient sustained a road traffic accident (RTA). There was no loss of consciousness. She was immediately admitted in the emergency unit of Laquintinie Hospital. Clinical examination did not revealed any sign of brain, chest or abdominal injury. There were painful deformations of left shoulder and thigh, X ray of which revealed displaced left humeral neck and closed transverse mid shaft fracture of the left femur, both requiring osteosynthesis. Except the fact that she was an asymptomatic heterozygote AS sickle cell patient, there was no other particular medical history.

Surgical intervention was performed one day later. Operative procedure consisted on open intramedullary Küntscher reamed Nail of 10 mm for the left femoral fracture and 3 Kirschner wires for the left humeral neck. Reaming of the femoral shaft was manually performed with an increment of 01 mm, till 12 mm.

There was no immediate post operative complication. Left upper arm was supported in a shoulder splint (Dessault). She was discharged 01 week later. Partial weight bearing was not allowed before 06 weeks.

She consulted 8 weeks later for routine control. There was no significant complain except low limited left shoulder range of motion (ROM) and moderated limp which was attributed to accommodation. There was full passive hip and knee ROM. No pain was detected.

Controlled X Ray revealed lysis of the outer cortex of all midshaft, mainly in the inner and posterior sides. There was a somewhat appearance of periosteal bone apposition at a certain distance from fracture, mainly on the proximal fragment. At fracture level, the lysis was almost totally on the inner side giving impression of an exposed nail (fig.1).



Figure 1: Follow up X ray of the left femur at 10 weeks; Lateral view

She was suspected of postoperative infection and readmitted. All blood tests (FBC, CRP, SR) were normal. Thigh puncture, performed under ultrasound, looking for any possible collection was also negative. Treatment consisted on bed rest and anti-inflammatory drugs. Two weeks later she started complaining of pain during partial weight bearing which was allowed for physiotherapy. X ray was then worse. Compact bone was fully destroyed posteriorly and no callus on fracture site was detected. Biology was still normal. Bone scan was performed at 4 months and revealed necrosis of the outer side of cortex at fracture level with some periosteal activity far from fracture and good osteoblast function on the inner side (fig. 2).

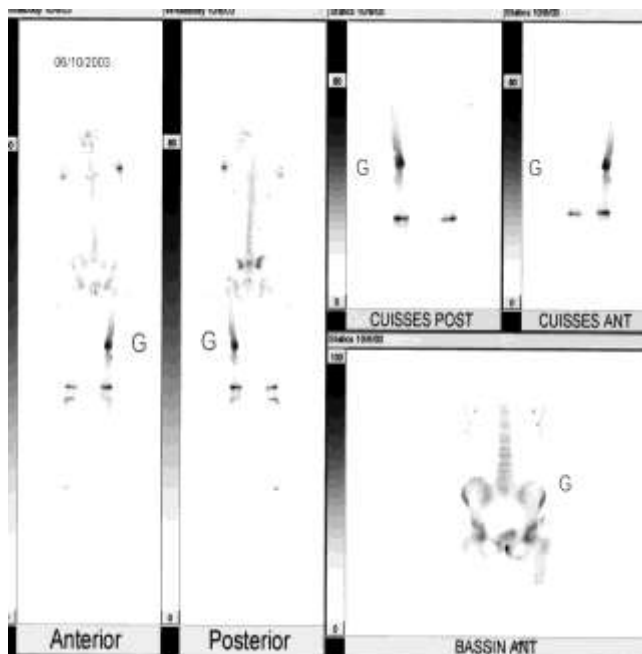


Figure 2: Bone scan, total body

We decided the removal of the nail while looking for further bone graft. One month later there was no more complain and X ray revealed fusion on the inner side and new bone apposition on the outer cortex (fig 3a). She was continuously seen 2 during years. There was no limp, no discrepancy and X- ray showed fully consolidated and reorganized callus (fig.3b).

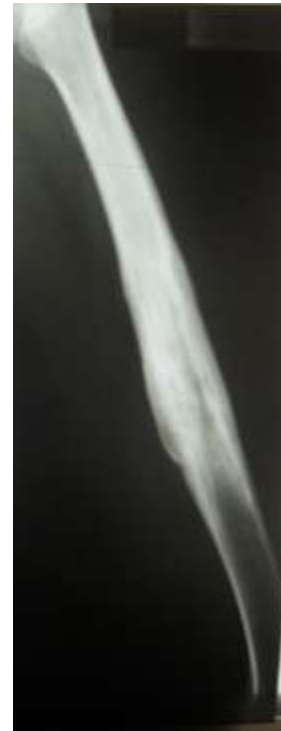
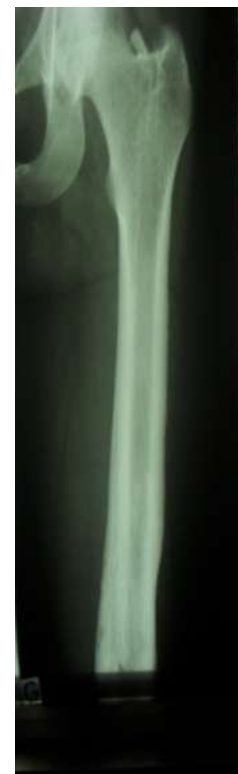
Figure 3a: Follow up X ray of the left femur one month after removal of the medullary nail



DISCUSSION.

Intramedullary nailing is a well known and admitted treatment of femoral fractures in elder children and adolescent. At those ages remaining growth potential is lesser and operative procedure does not involve the distal end of the femur which is more important for lower limb growth, compare to the greater trochanter. There are many reports of good results after intramedullary nailing in children and adolescents (1, 2).

Some complications have been also reported like avascular femoral head necrosis by destruction of the cervical arteries. These complications seem to be higher in children under 13 years (3). But to our best knowledge there is no reported case of segmental midshaft necrosis in children, linked to intramedullary nailing.

The 2/3 inner cortex is supplied by IM arteries otherwise periosteum provides the 1/3 outer cortex blood. Normally the blood flow is centrifuge.

In open procedure, IM nailing leads to destruction of the centromedullary blood supply is injured by both trauma and surgery. Periosteum can also be injured in attempts of fracture exposition and reduction.

Reaming not only destroys intramedullary vessels but induces heat and increases centromedullary pressure: these are higher risks factors of bone necrosis. It has been reported that risks factors of segmental necrosis after closed reaming are: blunt reamers, narrow canal diameter, higher speed of reaming, increment, great axial force and total reaming duration. These have lead to some reaming procedure modifications (4, 5).

In our case, we used open procedure in the absence of fluoroscopy. This has certainly destroyed an amount of periosteum. Even though the destruction involved the whole segment, it was marked in the outer aspect of the cortex where fracture was exposed and reduced. Periosteum at that level was certainly more injured.

Differential diagnosis in our case was post operative osteitis mainly because of extended cortical lysis. But there was no clinical or biological sign of infection: fever, pain swelling, high SR or CRP values. Thigh puncture and ultrasonography did not reveal any fluid collection. She did not receive any antibiotic.

Bone scan is particularly interesting. It was performed 4 months after operation. On the medial side of the fracture site, one can note good osteoblast activity. At the time, there was a progressive revascularization on that side which is less involved during open procedure. On the lateral side, there was no osteoblast activity. Cross section at that level denoted a C shape shaft confirming persistent necrosis at that side.

This segmental necrosis may be attributed to centromedullary reaming. But in that case, reaming was manually performed with a very low speed. Although increment was 1mm we did not encountered great resistance. The nail diameter was 1mm less than the maximal reamer diameter

Controlled X-ray revealed extended midshaft cortical lysis, even far from the fracture site. Curiously the lysis seemed to do not involve the inner cortex. In case of segmental bone necrosis reaming induced, there is often a large segment of dead bone from the inner cortex sometime surrounded by external reactive compact bone. This is explained by the vascular bone supply from the remaining non injured periosteum. It is therefore not consistent to attribute this necrosis only to reaming.

The necrosis appeared first on the medial side. It was secondary extended to the whole cross section. This is uncommon. Generally, when due to periosteum damage, necrosis is first located on the lateral side which may be torn during surgery. Even though she was an elder child, periosteum at that age is still hyper stimulated, like growth plates as can be seen on bone scan.

She is a heterozygote AS sickle cell patient. It is known that these patients can also exhibit bone manifestation of painful crisis (like the SS ones) with the same physiopathology.

It is possible that in this case, there were conjunctions of many factors which led to the segmental necrosis (periosteum damage in open procedure, reaming, AS heterozygote patient etc.).

This segmental necrosis suddenly disappeared after nail removal. This suggests there was a good revascularization of the cortex from IM supply.

CONCLUSION

Special attention must be paid to children or teens undergoing open intramedullary nailing. There is a risk of shaft necrosis which should not be confounded to osteitis. Recovery can be expected without any other procedure after nail removal.

CONFLIT D'INTERET

Aucun conflit d'intérêt n'est à relever dans le cadre de ce travail.

REFERENCES

- 1 Timmerman LA, Rab GT. Intramedullary nailing of femoral shaft fractures in adolescents. *J Orthop Trauma*; 7(4):331-337, 1993.
- 2 Clinkscales CM, Peterson HA. Isolated closed diaphyseal fractures of the femur in children: comparison of effectiveness and cost of several treatment methods. *Orthopedics* 1997; 20(12):1131-1136.
- 3 Gonwalez Herranz P, Burgos Flores J, Rapariz JM, Lopez Mondejar JA, et al. Intramedullary nailing of the femur in children. Effects on its proximal end. *J Bone Joint Surg Br* 1995; 77(2) : 262-266.
- 4 Pfeifer R, Sellei R, Pape HC. The biology of intramedullary reaming *Injury*. 41 Suppl 2010: S4-8.
- 5 Golpen G, Wilson JA, Mcaffrey M, Deluzio K et al. A cadaver model evaluating femoral intramedullary reaming: a comparison between new reamer. design (Pressure Sentinel) and a novel suction/irrigation reamer (RIA); *Injury*. 41 Suppl 2, 2010: S38-42.