

Clinical Case

Unusual Case of Total Left Common Iliac Artery Obstruction in a Young Sickle Cell Disease Patient

Occlusion de l'artère iliaque primitive gauche chez une adolescente drépanocytaire

Reddy Atipo-galloye^{1,2}, Sylvain Andre Ngounda Monianga¹, Lydie Ngolet³, Alexis Elira Dokekias³.

(1) : Polyvalent Surgical department, Brazzaville teaching hospital.
 (2) : Marien Ngouabi University, Faculty of Health Sciences, Brazzaville.
 (3) : Hematology Department, Brazzaville University Teaching Hospital.

Corresponding author : **Reddy Atipo-galloye**
 Assistant Professor in Cardiovascular Surgery
 Marien Ngouabi University, Faculty of Health Sciences

Polyvalent surgical department, , Brazzaville
 University Teaching Hospital. Republic of Congo.
 Email : reddyatipo@hotmail.fr

Tel : 00242065431560/00242050263851
 P.O. Box : Owando street N° 1189, Ouenze,
 Brazzaville.

Keywords : Iliac artery, obstruction, sickle cell disease, bypass.

Mots clés : Artère iliaque, occlusion, drépanocytose, pontage.

ABSTRACT

Vascular injuries are described as chronic complications in patients with homozygous sickle cell disease, which can lead to peripheral arterial obstruction. Emergency CT angiography is necessary to plan revascularization therapy. We report a case of young homozygous sickle cell disease patient, with total left iliac artery obstruction with presence of trophic disorders ; who underwent a femorofemoral crossover bypass and extremity amputation.

RÉSUMÉ

Les lésions vasculaires sont décrites comme des complications chroniques chez des patients présentant la drépanocytose homozygote, ce qui peut conduire à des occlusions des artères périphériques. Un angioscanner en urgence est nécessaire pour planifier la revascularisation. Nous rapportons le cas d'une jeune patiente drépanocytaire homozygote, avec occlusion de l'artère iliaque primitive gauche avec necrose du pied ; qui a bénéficié d'un pontage femorofemoral croisé associé à une amputation du tiers inférieur de la jambe.

INTRODUCTION

Sickle cell disease is a common genetic in sub-saharian Africa. This is caused by the persistence of fetal haemoglobin of adult age. Acute episodes of haemolysis are caused by environmental stress, and lead to acute and chronic cardiovascular disease. The pathogenesis involves chronic endothelial dysfunction by excessive oxidative stress and decreased bioavailability of NO [1]. Leg ulcerations have been along recognized cardiovascular complications, and the first sickle cell disease patient to be described in North America in 1910 had chronic leg ulcerations [2]. It is most common in sickle cell anemia.

In developing countries, where vasoocclusive crises are repetitive due to the lack of means by poor families, this situation may lead to development of vasculopathy, especially in lower limbs.

The localization at one of iliac arteries, causes ischemia of the affected pelvic limb. Not treated early

(revascularization), it will develop into trophic disorders of the limb then ulcer.

We present a case of young patient with homozygous sickle cell disease, and total iliac artery occlusion.

CASE PRESENTATION

A 16 year-old girl, homozygous drepanocytaire, from modest family, was transferred to our department by hematologist for dry left foot gangrene. Three weeks before, severe pain at rest. Physical exam revealed, fairly good general condition, with dry left foot gangrene (figure 1a), coldness of the left leg. All left pelvic limb pulses are absent, from the femoral pulse to the pedile pulse. Controlateral pulses are present.



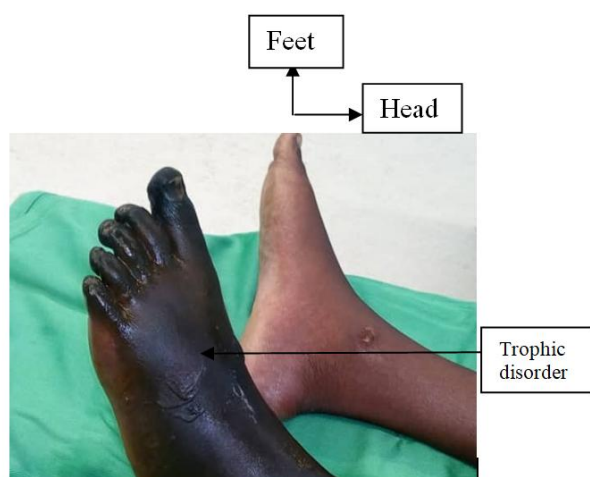


Figure 1a : Preoperative view, trophic disorders.

After three weeks, abdominal CT angiography revealed, total left primary iliac occlusion, with good arterial bed downstream (figure 1b). We decide to realize femorofemoral crossover bypass ; to optimize blood flow to the leg and minimize the level of amputation.

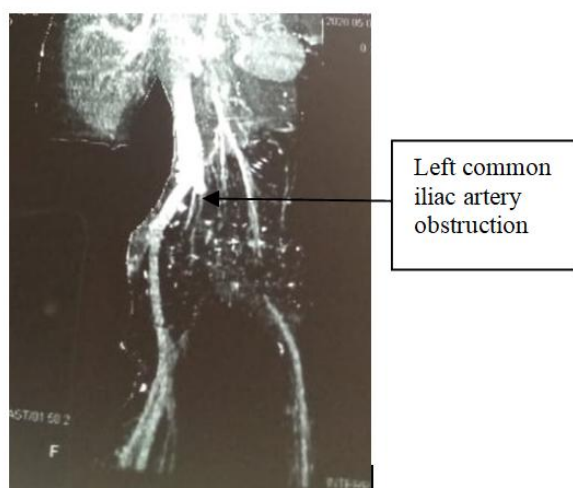


Figure 1b : Coronal CT angiography, showing left common iliac artery obstruction.

After obtaining written consent, under general anesthesia, first we had started by vertical incision of right scarpa, donor site (figure 2a). After dissection and liberation of common femoral artery, then we approach the receiving site. Right great saphenous vein has been harvested. After preparing the harvesting great saphenous vein with heparinized physiological serum, we realize first the anastomosis between distal part of the great saphenous vein and the donor site (figure 2a) with 5/0 polypropylene in continuo fashion. In the receiving site also, the anastomosis between proximal part of the vein and receiving site (figure 2b) with 5/0 polypropylene in continuo fashion ; after the passage of the pre-bladder space of Retzius. This revascularization has been completed by amputation of the lower third of the leg.

The postoperative period was uneventful.

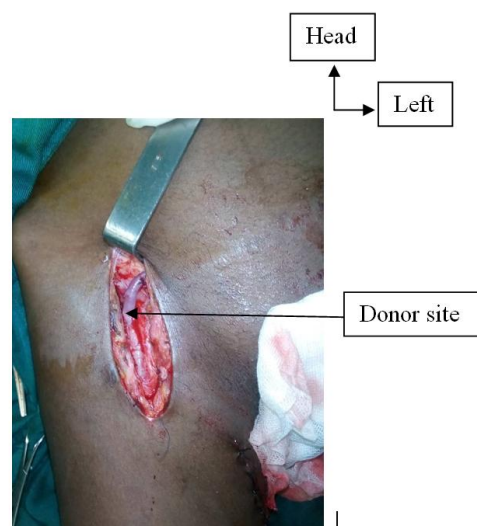


Figure 2a : Operative view, showing donor site anastomosis.

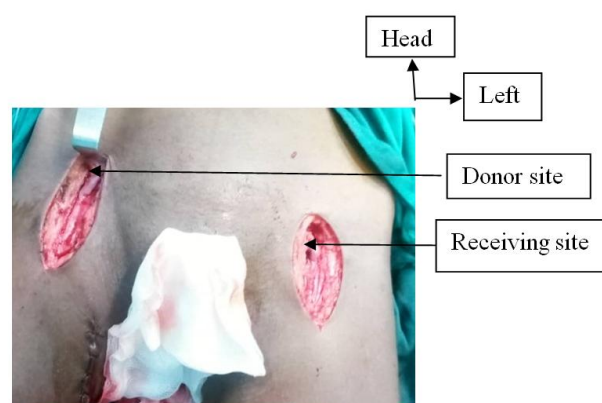


Figure 2b: Operative view, final aspect with two sites.

DISCUSSION

In sickle cell disease, there is chronic NO depletion which may contribute to vasoconstriction, proliferative vasculopathy, because NO is a potent inhibitor of platelet activation [1]. In this condition, if lower limb is concerned, progressively trophic disorders will evolve to leg ulcer [3]. The leg ulcer are painful. The pain may be severe, excruciating, penetrating. In our case, patient had severe pain. When acute limb thrombosis is suspicious, emergent CT angiography is mandatory, but our patient was from modest family, and did not afford the payment of this exam. This may explain the delay with which CT angiography has been realized.

Some authors have reported cases of limb arterial occlusion in other conditions. HIV patients with hypercoagulable state may develop arterial thrombosis, as described by Mulaudzi et al and Nair et al [4,5]. In different pathways, especially in systemic diseases as antiphospholipid antibody disease, hypercoagulable state has been also described by Asherson et al [6].

After diagnosis has been retained, the next step is rapidly propose revascularization therapy ; this may be by conventional surgery or endovascular approach. In our tertiary facility, endovascular approach is impossible, then the only option was conventional approach.

According to anatomic location of occlusion and the state of arterial bed below the obstruction, femorofemoral crossover bypass is the best option with prosthesis [7]. In Brazzaville teaching hospital, we don't have vascular prosthesis, in this way, we only have autologous great saphenous vein available.

The postoperative was uneventful, but patient decide to leave the hospital against medical advice on the fifth day.

CONCLUSION

Arterial occlusion may be various in etiologies, among them sickle cell disease especially in young patients in developing countries. Economic difficulties exposes to delayed diagnosis and risk of extremity amputation. Open surgery is the only revascularization option.

DECLARATION

Authors declare that there is no conflict of interest.

REFERENCES

1. Reiter CD, Wang X, Tanus-Santos JE, et al. Cell-free hemoglobin limits nitric oxide bioavailability in sickle-cell disease. *Nat Med* 2002 ;8 :1383–1389.
2. Herrick JB. Peculiar elongated and sickle-shaped red blood corpuscles in a case of severe anemia. 1910. *Yale J Biol Med* 2001;74:179–184.
3. M. Halabi-Tawil,* F. Lionnet, R. Giroto et al. Sickle cell leg ulcers: a frequently disabling complication and a marker of severity. *British Journal of Dermatology* 2008 158, pp339–344.
4. T.V. Mulaudzi,* J.V. Robbs, W. Pillay, B. Pillay et al. Thrombectomy in HIV Related Peripheral Arterial Thrombosis: A Preliminary Report. *Eur J Vasc Endovasc Surg* 2005 ;30 : 102–106.
5. R. Nair^{*1} , J. V. Robbs¹ , R. Chetty² , N. G. Naidoo¹ , J. Woolgar¹. Occlusive Arterial Disease in HIV-infected Patients: a Preliminary Report. *Eur J Vasc Endovasc Surg* 2000 ;2 : 353–357.
6. Ronald A. Asherson^a, Ricard Cervera^b, Yehuda Shonefeld^c. Peripheral Vascular Occlusions Leading to Gangrene and Amputations in Antiphospholipid Antibody Positive Patients. *Ann. N.Y. Acad. Sci.* 2007 ;1108: 515–529.
7. Laura Capoccia, Vincent Riambau, Marcio da Rocha. Is Femorofemoral Crossover Bypass an Option in Claudication?. *Ann Vasc Surg* 2010; 24: 828-832.