



Clinical Case

Alobar Holoprosencephaly: A Case Report and Review of the Literature

Holoprosencéphalie alobaire : à propos d'un cas et revue de la littérature.

Ananivi Sogan¹, Yaovi James¹, Wallace Etsri², Oni Djanikpo², Komlanvi Victor Adjénou^{2,3}, Komlanvi Denis James¹.

ABSTRACT

Holoprosencephaly is a rare cerebral malformation most often associated with suggestive cranio-facial abnormalities. It has several anatomical varieties, the most serious of which is the alobar form. Alobar holoprosencephaly represents in fact an ominous prognosis and can be part of a polymalformative syndrome. We report a case of alobar holoprosencephaly diagnosed on magnetic resonance imaging scan in the presence of congenital hydrocephalus without facial abnormalities.

(1) Human Anatomy Laboratory, Faculty of Health Sciences, University of Lomé (Togo).
 (2) « Autel d'Elie » Clinic, Lomé (Togo).
 (3) Medical Imaging Department, Hospital and University Center Campus, Lomé (Togo).

Corresponding author:

Ananivi SOGAN

MD, Surgeon

Assistant professor in anatomy at Faculty of Health Sciences, University of Lomé (Togo).

E-mail: sopher2@hotmail.fr

Tel: (00228) 91 92 71 18

Keywords: alobar holoprosencephaly, hydrocephalus, magnetic resonance imaging scan.

Mots clés : holoprosencéphalie alobaire, hydrocéphalie, imagerie par résonance magnétique.

RÉSUMÉ

L'holoprosencéphalie est une malformation cérébrale rare le souvent associée à des anomalies cranio-faciales évocatrices. Elle présente plusieurs variétés anatomiques dont la plus grave demeure la forme alobaire. L'holoprosencéphalie alobaire est en effet de pronostic sombre et peut s'inscrire dans un contexte de syndrome polymalformatif. Nous rapportons un cas de l'holoprosencéphalie alobaire diagnostiqué à l'imagerie par résonance magnétique devant une hydrocéphalie congénitale sans anomalies faciales.

INTRODUCTION

Holoprosencephaly (HPE) represents a nosological entity grouping together cerebral malformations that have in common a disorder of the cleavage of the cerebrum (telencephalon) into left and right cerebral hemispheres. It is a gastrulation abnormality occurring between the 18th and 28th day of intra-uterine life with one in 10,000 or 16,000 living newborns and with four in 1,000 embryos. HPE shows an identical prevalence in all human populations aside from in Southeast Asia where it seems to be more common [1-3]. Several anatomical varieties of HPE are recognized, the most severe of which remains the alobar form characterized by a complete absence of division of the primitive brain into hemispheres [2]. The aim of this observation is to review the different aspects of HPE through a case of alobar HPE diagnosed at "Autel d'Elie" Clinic (AEC) in Lomé (Togo).

OBSERVATION

A 30-day-old male newborn, the couple's first child, was seen in the AEC medical imaging department for magnetic resonance imaging (MRI) scan so as to investigate a hydrocephalus with congenital moderate macrocephaly. It is a question of a newborn from a poorly monitored pregnancy with a third trimester ultrasound

scanning suggestive of hydrocephalus. The mother, aged 26 years, had no known pathological history or chronic pathology. There was no notion of consanguinity. The investigation did not find any teratogenic drugs taken during pregnancy. Clinically, there was no facial malformation, the sucking reflex was present but automatic walking and grasping were impossible; the head circumference was 39.5 cm (+2 SD); the height was 50 cm (-2 SD) and the weight 4 kg (-1 SD). The MRI scan of the encephalon revealed: a single hyper T2, hypo T1 and Flair fluid cavity pushing forward the remaining cerebral parenchyma (Figures 1 and 2) giving a "horseshoe" appearance (Figure 3), absence of the callosal commissure (corpus callosum), absence of bulbo-peduncular and cerebellar hemispheres morphological abnormalities, a fourth ventricle with a normal appearance and an arterial circle of the base of the brain with no abnormality. The abnormalities of the supratentorial structures are characteristic and have enabled us to retain the diagnosis of alobar HPE without associated facial malformation. The newborn was referred to the neurosurgery department where he was followed up: monitoring of the hydrocephalus and the cranial perimeter which were stable and did not yet require a bypass, a thyroid check-up and an ionogram which were normal.

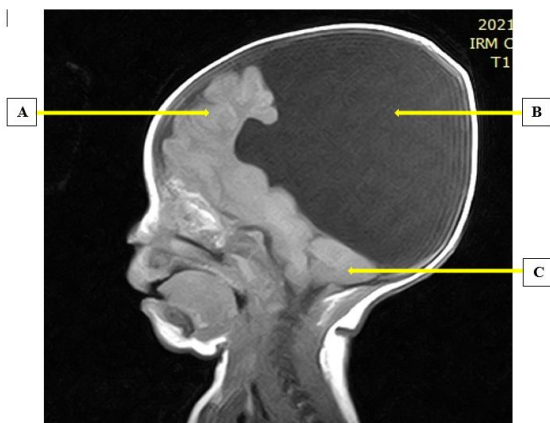


Figure 1: MRI scan of the encephalon in sagittal section displaying a single dilated supratentorial cavity pushing forward the remaining cerebral parenchyma: **A=** Remaining cerebral parenchyma, **B=** Single dilated cavity, **C=** Cerebellum (little brain)

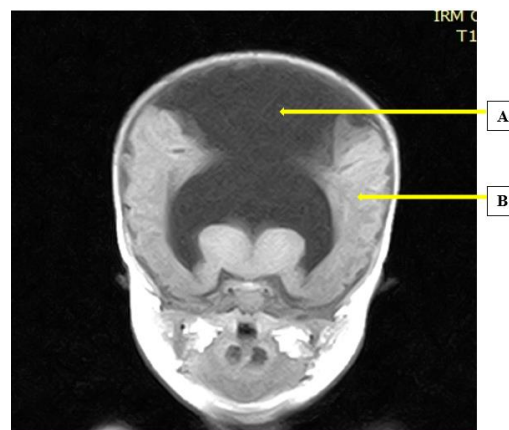


Figure 3: MRI scan of the encephalon in frontal section displaying a single dilated cavity giving the rest of the parenchyma a horseshoe appearance. **A=** Single dilated cavity, **B=** Remaining cerebral parenchyma.

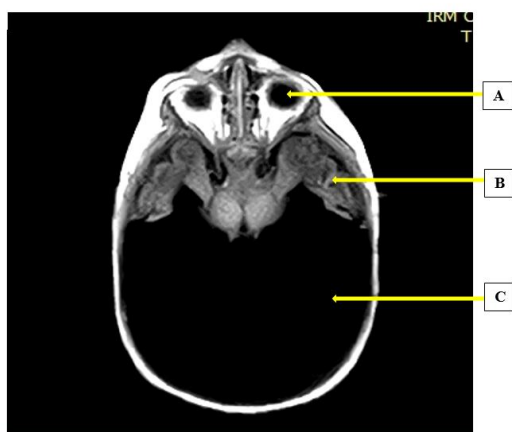

Figure 2: MRI scan of the encephalon in axial section displaying a single dilated supratentorial cavity pushing forward the remaining cerebral parenchyma. **A=** Left orbital cavity, **B=** Remaining cerebral parenchyma, **C=** Single dilated cavity

DISCUSSION

HPE is the translation of the defect of ventral induction of the prosencephalon at the level of the mesodermal prechordal blotch after, during, but also before, the closure of the neural tube. Classical HPE is more specifically due to the cleavage defect of the telencephalic vesicles [1]. The spectrum of malformations ranges from very severe to classic and minor forms. The most severe forms are thought to result either straight from a defect in the induction of the prosencephalon (aprosencephaly), or from a defect in the appearance of the telencephalon (atelencephaly) due to a budding defect. At the other end of the spectrum, arhinencephaly can represent a minor form of HPE as can septo-optic dysplasia [1]. Depending on the complete or incomplete absence of the interhemispheric sulcus, there are classically three anatomical varieties of HPE of decreasing severity: the alobar, semi-lobar and lobar form. A fourth form or medial interhemispheric merger is also considered [1, 4] (Table).

Table :Anatomical varieties of HPE and their characteristics				
Anatomical varieties	Alobar Holoprosencephaly	Semi-lobar Holoprosencephaly	Lobar Holoprosencephaly	Syntelencephalia
Characteristics	Absence of inter-hemispheric sulcus Absence of V3 Single dilated cerebral ventricle No callosal commissure Absence of tract and olfactory bulb Fusion of the basal ganglia	Incomplete interhemispheric sulcus Rudimentary cerebral hemispheres Draft of V3 No callosal commissure Absence or hypoplasia of the bulbs and olfactory tracts Partial fusion of the basal ganglia	Entirely developed cerebral hemispheres Distinct interhemispheric sulcus Continuous frontal neocortex on the midline Callosal commissure absent, hypoplastic or normal. Separation of the basal ganglia	Dorsal fusion of frontal, parietal and dorsal areas Vertical and continuous sylvan valleys in each other on the median line.

HPE is a rare cerebral malformation with which other abnormalities may be associated, the main one being

facial dimorphism, "the face predicts the brain", it is said [1]. Other neurological, cardiac and genital abnormalities

are not excluded, making HPE part of a polymalformative syndrome [5]. During morphogenesis, the inductive role of the nervous system in the construction of the cephalic pole (skull, face and neck) between the 4th and 10th week of development explains the frequent association of malformations of the face and the brain [1]. Cyclopia, hypotelorism, pseudonasal median appendix and a median cleft lip are most often associated with alobar HPE. Less severe facial dysmorphisms including ocular hypotelorism, coloboma of the iris, absence of nasal bone, single central incisor, cleft lip or palate and midface hypoplasia may be associated with all anatomical forms of the disease [1]. However, whatever the anatomical form or the severity of the cerebral malformation, the face can be normal as in our observation.

From an etiopathogenic point of view, HPE is a multifactorial pathology in which environmental and genetic factors are intertwined [1, 6]. Environmental factors are represented by maternal pathologies and exposures. Maternal diabetes is the best known predisposing factor with a 1% risk of developing HPE. Cytomegalovirus, rubella and toxoplasmosis infections in a pregnant woman are also risk factors for the occurrence of HPE. Ethylism, tobacco addiction and treatments with carbazepine, valproate, phenytoin, primidone, aspirin, misoprostol, methotrexate, statins and retinoic acid during pregnancy are teratogenic and implicated in the occurrence of HPE [1]. Genetic factors include cytogenetic (chromosome number or structure) and molecular abnormalities.

About 40% to 60% of HPE are seen in multiple chromosome number or structural abnormalities [7]. Chromosomal number abnormalities include trisomy 13, trisomy 18, trisomy 21, trisomy 22 and triploidy. HPE is often seen in people with trisomy 13 [7]. People with HPE from chromosomal causes are more likely to have at least one other malformation. The most frequently reported structural chromosomal abnormalities associated with HPE are deletions (del) or duplications (dup). The regions affected by structural abnormalities are (13q), del (18p), del (7) (q36), dup (3) (p24-pter), del (2) (p21) and del (21) (q22.3). There are 12 regions (noted HPE1 to HPE2) located on 11 loci containing the genes (16 in total) involved in the occurrence of HPE [6, 7].

The existence of molecular abnormalities makes it possible to distinguish two categories of HPE: syndromic and non-syndromic. At least 25 different syndromes in which HPE is occasionally present have been described; the majority of these diseases are rare and of autosomal recessive (e.g. Smith-Lemli-Opitz syndrome) or dominant (e.g. Pallister-Hall syndrome) transmission [7]. In consanguineous families, the autosomal recessive mode of transmission of some mutations has been demonstrated. However, in most families, it is a question of multigenic or even multifactorial heredity, involving some environmental factors. African authors have reported cases of HPE in consanguineous couples [5, 8].

HPE is characterized in newborn babies by a clinical polymorphism related to the involvement of the telencephalon and diencephalon where the structures that constitute the conductor of the endocrine system are

located [9]. Delayed psychomotor development is the most frequent manifestation. This delay was noted in the reported case. Its severity is proportional to the severity of the cerebral malformation. Epileptic seizures are frequent and can be difficult to control. Depending on the anatomical forms, there is either microcephaly or macrocephaly with hydrocephalus. In our case, it was about a form of HPE with hydrocephalus, which is the preserve of alobar forms of the pathology.

Disorders in the regulation of temperature, heart rate, respiratory rate and swallowing are observed in relation to damage to the hypothalamus and brainstem, the centers of vegetative life. The swallowing or feeding disorders observed in newborns with cleft lip, palate or labio-palate are of a severity that is related to the severity of the cerebral malformation. From the damage of the hypothalamus and therefore of the hypothalamo-hypophyseal axis, a panel of endocrine disorders represented by: panhypopituitarism with diabetes insipidus, hypothyroidism, corticotrophic insufficiency and a collapse of the production of growth hormone [8]. The endocrinopathy associated with the pathology constitutes a deciding factor of the morbi-mortality in HPE.

The diagnosis of HPE is first made by routine foetal ultrasound in experienced hands during pregnancy follow-up even though its diagnostic sensitivity is outweighed by the minor forms of the malformation [10]. Foetal MRI scan should be the morphological workup of choice in cases of suspected cerebral malformation because of its diagnostic sensitivity, which surpasses that of ultrasonography and computed tomography scan within the exploration of the central nervous system during intra- and extra-uterine life [10]. The diagnosis was made on the basis of the MRI images in our neonatal observation. Karyotyping and molecular testing are not essential for the diagnosis. However, the knowledge of cytogenetic abnormalities that may be associated facilitates genetic counseling and predicts the prognosis of viable forms of the malformation [10].

The care of HPE remains complex and challenging, which can only be attempted by a multidisciplinary team [10]. It may use drug treatments (hormone replacement, antiepileptic drugs, feeding tube, rehabilitation medicine, close monitoring) and/or surgical treatments (gastrostomy tube, cleft lip and palate repair, ventriculo-peritoneal bypass). Regardless of the care modalities, HPE in these anatomical varieties remains a pathology with a bleak prognosis.

CONCLUSION

HPE is a rare and multifaceted illness, the severe form of which is the alobar variety. It can be isolated or associated with other malformations in the context of a polymalformative syndrome. We have reported a case of the alobar form with hydrocephalus and moderate macrocephaly without facial malformation which enabled us to review the different aspects of the disease. In view of the difficulties of care and the bleak prognosis of HPE, particular emphasis should be placed on genetic counseling and on avoidable risk factors.

REFERENCES

1. Demyer W, Zeman W. Alobar holoprosencephaly (arhinencephaly) with median cleft lip and palate: clinical, electroencephalographic and nosologic considerations. *Confin Neurol.* 1963; 23:1–36.
2. Orioli IM, Castilla EE. Epidemiology of holoprosencephaly: prevalence and risk factors. *Am J Med Genet Part C Semin Med Genet.* 2010; 154C:13–21.
3. Matsunaga E, Shiota K. Holoprosencephaly in human embryos: epidemiologic studies of 150 cases. *Teratology.* 1977; 16:261–72.
4. Delezoide AL, Narcy F, Larroche JC: Cerebral midline developmental anomalies: spectrum and associated features. *Genet Couns.* 1990, 1(3-4):197-210.
5. Nanni L, Schelper R, Muenke M. Molecular genetics of holoprosencephaly. *Front Biosci.* 2000; 5:334–42.
6. Kruszka P, Muenke M. Syndromes Associated with Holoprosencephaly. *Am J Med Genet C Semin Med Genet.* 2018; 178(2): 229–237. doi:10.1002/ajmg.c.31620.
7. Amadou DA, D'Almeida F, Mbodji M, Mourtalla KM. Holoprosencephalie alobaire dans un contexte de syndrome polymalformatif : apport de l'imagerie, à propos d'un cas. *Pan African Medical Journal.* 2013; 15:83. doi:10.11604/pamj.2013.15.83.2797
8. Seck N, Basse I, Keita Y, Boiro D, Thiam L, Ndongo AA, Diagne I. Holoprosencéphalie alobaire avec diabète insipide et hypothyroïdie chez un nourrisson de 10 mois. *Pan African Medical Journal.* 2017; 28:193. doi:10.11604/pamj.2017.28.193.11288
9. Raam MS, Solomon BD, Muenke M. Holoprosencephaly: a guide to diagnosis and clinical management. *Indian Pediatr.* 2011; 48:457–66.
10. Hahn JS, Plawner LL. Evaluation and management of children with holoprosencephaly. *Pediatr Neurol.* 2004; 31:79–88.