



Clinical Case

Monocular Blindness and Plexiform Neurofibromas in Association to Neurofibromatosis Type 1: A Report of Two Pediatric Cases

Cécité monoculaire et neurofibromes plexiformes associés à une neurofibromatose de type 1: à propos de deux cas pédiatriques

Laouali Laminou^{1a}, Hassane A Traoré^{2c}, Abba Kaka Y^{3b}, Amza Abdou^{4b}

1: Department of Ophthalmology, Zinder National Hospital.
 2: Department of Ophthalmology, Maradi Regional Hospital Center.
 3: Department of Ophthalmology, Niamey National Hospital.
 4: Ophthalmology Department, Amirou Boubacar Diallo Hospital, Niamey.
 a: Université André Salifou de Zinder, Niger.
 b: Université Abdou Moumouni Dioffo de Niamey, Niger.
 c: Université de Maradi, Niger.

^{1a}**Corresponding author:** Laouali Laminou, Ophthalmologist, Faculty of Health Sciences, André Salifou University of Zinder, Niger. BP: 656 Zinder, Niger; Fax: 00227 20510920.
 E-mail: elaminelaouali@gmail.com

Keywords: Neurofibromatosis type 1, plexiform neurofibroma, monocular blindness, congenital glaucoma, child, Zinder, Niger

Mots clés: Neurofibromatose de type 1, neurofibrome plexiforme, cécité monoculaire, glaucome congénital, enfant, Zinder, Niger

RÉSUMÉ

Neurofibromatosis type I (NF1) or Von Recklinghausen disease is one of the most common genetic diseases with polyvascular manifestations, including the eye. Its prevalence was variously estimated varying between 1/7800 and 1/2000. The diagnosis of NF1 is essentially clinical based on criteria established by the consensus conference of the National Institute of Health (NIH) in 1988. Several complications have been reported by numerous authors in cases of plexiform neurofibromas sometimes associated with congenital glaucoma. We report two cases of monocular blindness in children that were complications of NF1 and that were at the origin of stigmatization by their peers and school dropout. Both cases were seen at the National Hospital of Zinder, Niger.

ABSTRACT

La neurofibromatose de type I (NF1) ou maladie de Von Recklinghausen est l'une des maladies génétiques les plus fréquentes à manifestations polyviscérales, l'œil y compris. Sa prévalence était diversement appréciée variant entre 1/7800 à 1/2000. Le diagnostic de la NF1 est essentiellement clinique basé sur des critères établis par la conférence de consensus de la National Institute of Health (NIH) en 1988. Plusieurs complications ont été rapportées par des nombreux auteurs en cas de neurofibromes plexiformes parfois associés au glaucome congénital. Nous rapportons deux cas de cécité monoculaire chez des enfants, complications de la NF1 et responsables d'une stigmatisation par leurs pairs avec abandon scolaire. Les deux cas ont été vus à l'Hôpital National de Zinder, Niger.

INTRODUCTION

Neurofibromatosis type 1 is an autosomal dominant genetic neurocutaneous disorder in which the gene responsible for the mutation was located on chromosome 17 in the 17q11.2 region in 1990. [1,2]. It was in 1882 that Friedrich Daniel Von Recklinghausen described for the first time the nervous origin of the tumors observed in the disease that would later bear his name [3]. Its penetrance is close to 100% around the age of 5 years and de novo mutations occur in about 50% of cases [4]. The diagnosis of neurofibromatosis type 1 is clinical based on criteria (Table I) established in 1988 by the consensus conference of the National Institute of Health (NIH/CDC) [5]. Several complications could occur during the course of Von Recklinghausen disease and the eye is not spared. We report in this work two cases of monocular blindness due to NF1 seen at the National Hospital of Zinder. The parents gave informed consent for the publication.

Panel : NIH consensus criteria for diagnosis of neurofibromatosis type 1 (1988)^[5]

Two or more the following clinical features are sufficient to establish a diagnosis of neurofibromatosis type 1

1. Six or more café-au-lait macules (> 0.5 cm at largest diameter in a prepubertal child or > 1.5 cm in post-pubertal individuals)
2. Axillary freckling or freckling in inguinal regions
3. Two or more neurofibromas of any type or one or more plexiform neurofibromas
4. Two or more Lisch nodules (iris hamartomas)
5. A distinctive osseous lesion (sphenoid wing dysplasia, long-bone dysplasia)
6. An optic pathway glioma
7. A first degree relative with neurofibromatosis type 1 diagnosed by the above criteria

NIH : National Institute of Health

CASE 1

M.B., female, 8 years old, monophthalmic right eye, with a family history of neurofibromatosis. She was dropped out of school in the first grade because of the stigma attached to her disease by children her age. She had undergone evisceration of her left eye at the age of 5 years after failed trabeculectomy treatment at the age of 2 years for unilateral congenital glaucoma of the left eye (Figure 1A, red arrow). On ophthalmologic examination, the distance visual acuity on the right eye was 10/10 and there was no light perception on the left eye. The adnexa examination, noted a purulent conjunctivitis and a total ptosis covering an anophthalmic orbital cavity (Figure 1B), normal adnexa on examination of the right eye, a clear cornea, a quiet anterior chamber, Lish's iridal nodules with a reactive pupil (figure 1D). Dermatological examination noted several café au lait spots, numerous skin nodules, and a plexiform neurofibroma on the left upper eyelid resulting in total mechanical ptosis (Figure 1C yellow arrow). A CT scan of the orbitocerebrum was requested and was unremarkable except for the palpebral mass. The diagnosis of neurofibromatosis type 1 was retained, treatment with eye drops and antibiotic ointment was administered and the patient was referred for reconstructive surgery.

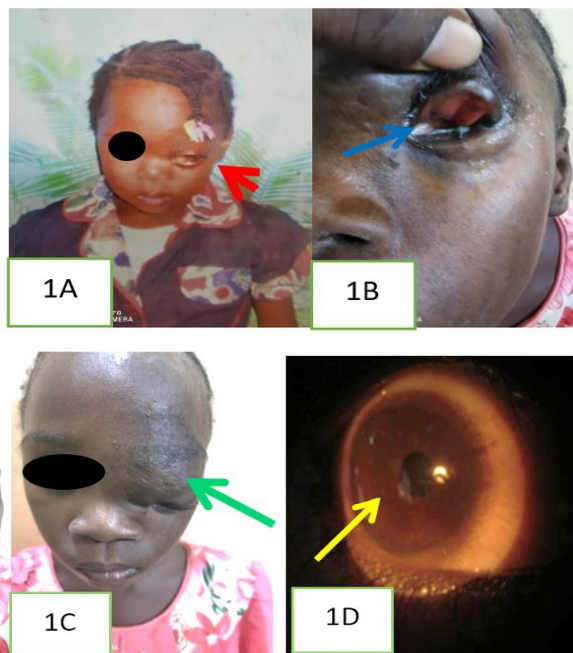


Figure 1 : **1A :** Congenital glaucoma left eye (red arrow), **1B :** anophthalmia and conjunctivitis left eye (blue arrow), **1C** plexiform neurofibroma on the left upper eyelid resulting in total mechanical ptosis (green arrow), **1D :** Lish Nodules right eye (yellow arrow)

CASE 2

A.B, male, 15 years old, monophthalmic with right eye, having dropped out of school because of stigmatization by his schoolmates and engaging in begging, was brought by his mother to the ophthalmology department of the Nation Hospital in Zinder for swelling in the orbit and hanging from the left hemiface, with facial dysmorphia. (Figure

2A red arrow). No family history of disease was reported. On ophthalmologic examination, visual acuity was 10/10 on the right and see move hand. Biomicroscopic examination of the right eye revealed normal adnexa, a healthy cornea with a good quiet anterior chamber, Lish nodules (figure 2 B blu arrow) with a normal fundus. Examination of the left eye, hampered by swelling, revealed conjunctivitis, a 360° corneal pannus with a corneal opacity, all of which made examination of the anterior segment difficult. The dermatological examination noted a plexiform neurofibroma hanging from the orbito-periorbital area and involving the left hemiface (Figure 2A), café au lait spots, skin nodules and axillary lentigines. The diagnosis of neurofibromatosis type 1 was retained, a treatment based on antibiotic eye drops was administered and the patient was referred for maxillofacial surgery.

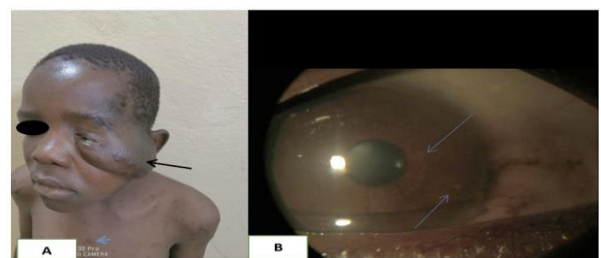


Figure 2: **2A** orbito-periorbital plexiform neurofibroma appended to the left temporal area with facial dysmorphia (black arrow), **2B** Lisch nodules (blue arrow).

DISCUSSION

Neurofibromatosis type I (NF1) is a heterogeneous group of diseases characterized by a genetically determined predisposition to the development of benign or malignant polyvisceral tumors, including ocular ones [6]. Its prevalence was variously estimated ranging from 1/7800 to 1/2000. It is one of the most frequent genetic diseases [7-10]. Its diagnosis is essentially clinical based on criteria established by the NIH (Table 1). Several complications have been reported by numerous authors in cases of plexiform neurofibromas. These occur in 30-50% of patients with NF1 [11,12]. These tumors were reported in our two patients with various localizations but all involving the upper eyelids of the left eye. Congenital glaucoma is a complication of NF1 [13]. It can be bilateral or unilateral as was the case in our 1st patient. She presented the Jules François syndrome described by the author who bore his name in 1956 [14].this syndrome associates an early congenital glaucoma, a plexiform neurofibroma of the homolateral upper eyelid and a facial hemihypertrophy. The etiopathogenic mechanisms are multiple: infiltration of the Schwann sheath of the ciliary nerves (neurofibromas) that block the iridocorneal angle, malformation or immature development of the iridocorneal angle, uveal ectropion ... [13,14] etc.... The treatment of congenital glaucoma in NF1 is complex. It requires surgery with disappointing results, as in the case of our patient whose eye was eventually eviscerated, thus rendering the patient monophthalmic. In the majority of

cases, this glaucoma occurs on the same side as the palpebral plexiform neurofibroma with the secondary appearance of buphthalmia [14]. In the case of plexiform neurofibroma, exophthalmos was present in 25% of cases. It was found in our 2nd patient (50%), responsible for facial dysmorphism and left unilateral blindness, blindness being defined by the World Health Organization (11th International Classification of Diseases 2018) as a visual acuity of less than 3/60 [15]. Orbital involvement due to plexiform neurofibroma growth is rare and considered pathognomonic of NF1 with several designations: Orbitotemporal neurofibromatosis, orbitofacial neurofibromatosis, cranioorbital neurofibromatosis, cranioorbital-orbito-temporal neurofibromatosis and recently a working group had suggested the term orbital-periorbital plexiform neurofibromas to encompass all sites of localization [14,16]. Cognitive and behavioral disorders occur in 46-80% of children with NF1. Specific learning disabilities affecting performance on visuospatial tasks, reading and writing skills, and oral and written expression often lead to poor school performance [17]. Both of our patients dropped out of school due to stigmatization and marginalization and both were engaged in begging. This stigma would negatively impact the quality of life of these patients who would feel inferior. In a study of 129 patients with NF1, the authors noted a greater degree of psychological distress in patients with NF1 than in the general population [18]. All diagnoses taken together, psychiatric pathologies are much more frequent in neurofibromatosis type 1 than in the general population with a prevalence of 33% [19], even if some authors estimated that these pathologies were underdiagnosed.

CONCLUSION

Von Recklinghausen disease is a genetic disease with polyvisceral manifestations. The ophthalmologist has a central role not only in the diagnosis and management of NF1, but also in the detection of certain ocular complications, some of which may jeopardize the visual prognosis through blindness that is often irreversible. In the chain of care of NF1, which is meant to be holistic, psychologists and psychiatrists are not left out because of the stigmatization of NF1 patients.

DISCLOSURE STATEMENT

No conflict of interest is reported by the authors.

ACKNOWLEDGEMENTS

We sincerely thank the parents of the children who agreed to participate in this work and the administration of the National Hospital of Zinder for performing certain examinations free of charge.

REFERENCES

[1] Aidara CM, Diop D, Ndiaye OK, Diop AD, Ndiaye MA, Diop AN, et al. Apport de l'imagerie dans la neurofibromatose de type 1. Feuilles de Radiologie. févr 2015;55(1):31-6.
 [2] Ferner RE, Huson SM, Thomas N, Moss C, Willshaw H, Evans DG, et al. Guidelines for the diagnosis and management of individuals with neurofibromatosis 1. Journal of Medical Genetics. 11 août 2006;44(2):81-8.

[3] James A. Walker & Meena Upadhyaya (2018): Emerging therapeutic targets for neurofibromatosis type 1, Expert Opinion on Therapeutic Targets, DOI: 10.1080/14728222.2018.1465931
 [4] Longo JF, Weber SM, Turner-Ivey BP, Carroll SL. Recent Advances in the Diagnosis and Pathogenesis of Neurofibromatosis Type 1 (NF1)-associated Peripheral Nervous System Neoplasms. Advances in Anatomic Pathology. sept 2018;25(5):353-68.
 [5] National Institutes of Health, Neurofibromatosis: Conference Statement. Arch Neurol. 1 mai 1988;45(5):575-578 doi:10.1001/archneur.1988.00520290115023
 [6] Dollfus H, Richard S et Flament J. Phacomatoses et oeil. Encycl Méd Chir (Editions Scientifiques et Médicales Elsevier SAS, Paris, tous droits réservés), Ophtalmologie, 21-470-D-20, 2000, 11 p.
 [7] Morabite KE, Hassam B. La neurofibromatose de type I. Pan Afr Med J 2014;17. Disponible sur: <http://www.panafrican-med-journal.com>
 [8] Friedman JM. Epidemiology of neurofibromatosis type 1. Am J Med Genet. 26 mars 1999;89(1):1-6.
 [9] Poyhonen M. Epidemiology of neurofibromatosis type 1 (NF1) in northern Finland. Journal of Medical Genetics. 1 août 2000;37(8):632-6.
 [10] Odebode TO, Afolayan EAO, Adigun IA, Daramola OOM. Clinicopathological study of neurofibromatosis type 1: an experience in Nigeria. Int J Dermatol. févr 2005;44(2):116-20.
 [11] Angela C Hirbe, David H Gutmann Neurofibromatosis type 1: a multidisciplinary approach to care Lancet Neurol 2014; 13: 834-43
 [12] Peltonen S, Kallionpää RA, Peltonen J. Neurofibromatosis type 1 (NF1) gene: Beyond café au lait spots and dermal neurofibromas. Exp Dermatol. juill 2017;26(7):645-8.
 [13] Nazih Tzilih et al. Le glaucome congénital et la neurofibromatose de type 1. Pan African Medical Journal. 2015; 21:56 doi:10.11604/pamj.2015.21.56.6794
 [14] François J, Haustrate L, Philips A. Unilateral hydrophthalmia and homolateral hemifacial hypertrophy (Von Recklinghausen's neurinomatosis). Ann Ocul (Paris). 1956 Feb ;189(2) :186-202.
 [15] Organisation mondiale de la santé (OMS). Cécité et déficience visuelle. Disponible sur: <https://www.who.int/fr/news-room/fact-sheets/detail/blindness-and-visual-impairment>
 [15] Rilliet B, Pittet B, Montandon D, Narata AP, de Ribaupierre S, Schils F, et al. L'atteinte orbito-temporo-faciale dans la neurofibromatose de type 1 (NF1). Neurochirurgie. avr 2010;56(2-3):257-70.
 [16] Derancourt C, et al. Caractéristiques de la neurofibromatose de type 1 en Martinique : étude préliminaire. Ann Dermatol Venerol (2014), <http://dx.doi.org/10.1016/j.annder.2014.09.011>
 [17] Domon-Archambault V, Gagnon L, Benoît A, Perreault S. Psychosocial Features of Neurofibromatosis Type 1 in Children and Adolescents. J Child Neurol. mars 2018;33(3):225-32.
 [18] Belzeaux R, Lancon C. Neurofibromatose de type 1. Troubles psychiatriques et altérations de la qualité de vie. Presse Med 2006 ; 35 :277-80.
 [19] Spaepen A, Boeghgraef M, Fryns JP. Von Recklinghausen neurofibromatosis : a study of the psychological profile. Birth Defects Orig Artic Ser 1992 ;28 :85-91

