

## Case Report

# Laparoscopic Surgery for Inguinal Hernia in Adult Patients: A Case Report of a Transabdominal Pre-Peritoneal Repair in the National Social Insurance Fund Health Center of Essos (Yaoundé)

Nana Oumarou Blondel<sup>1,2</sup>, Bang Guy Aristide<sup>1</sup>, Savom Eric Patrick<sup>1</sup>, Guifo Marc Leroy<sup>2</sup>, Ekani Boukar Yannick Mahamat<sup>1</sup>, Ousmana Oumarou, Essomba Arthur.<sup>2</sup>

<sup>1</sup> Visceral and laparoscopic surgery unit, National Social Insurance Fund Health Center of Essos (Yaoundé/Cameroon).

<sup>2</sup> Department of surgery and specialties, Faculty of Medicine and Biomedical Sciences, University of Yaoundé I (Cameroon).

**Corresponding author.** NANA OUMAROU Blondel, Visceral and laparoscopic surgery unit, National Insurance Health center of Essos (Yaoundé/Cameroon). E-mail: [nanablondel@yahoo.fr](mailto:nanablondel@yahoo.fr) . Phone number : +237679539464

## ABSTRACT

Inguinal hernia repair is probably the most common procedure in general surgery. Today, in adult hernias, prosthetic repairs are accepted to be superior to “non-mesh” suture repairs. Concerning mesh repair, the (open) Lichtenstein and laparoscopic inguinal hernia techniques are recommended as the best evidence-based options. Nevertheless laparoscopic techniques still not currently practiced in our country.

We report a case of a 57 years-old male patient who presented with a left inguinal hernia managed by a transabdominal pre-peritoneal (TAPP) repair. With the patient under general anesthesia, we placed three trocars, the optic one inserted by “open-coelioscopy”. We realized a peritoneal incision 4 cm

above the left inner inguinal ring. The peritoneal sac was dissected from the spermatic cord and transected. A polyester mesh with a self-gripping overlapping flap was then inserted into the pre-peritoneal space created. A Thorough closure of the peritoneal incision was done. The post-operative course was uneventful. In conclusion, laparoscopic hernias repairs in general and TAPP in particular are easy to teach and learn. Surgeons and residents should be trained on it.

**Keywords.** Inguinal hernia, transabdominal pre-peritoneal repair. Inguinal hernia, laparoscopy

## INTRODUCTION

Inguinal hernia repair is probably the most common procedure in general surgery [1]. The groin is a naturally weak point in the abdominal wall. This weakness is referred to anatomically as the myopectineal orifice of Fruchaud. The failure of the fascia transversalis to retain the peritoneum/preperitoneal fat is the fundamental cause of inguinal hernia. This fascia is weakened by congenital or acquired factors on the one hand and pressure increasing events on the other.

Inguinal hernias are corrected by repairing the fascial defect in the myopectineal orifice of Fruchaud or by reinforcing the weakened fascia transversalis and bridging the defect by inserting prosthesis (mesh). Numerous repair techniques have been described since Eduardo Bassini had published his first anatomy-based repair with great success in 1890. But two revolutions in inguinal hernia surgery have occurred during the past three decades. The first was the introduction of tension-free open mesh repair by LICHENSTEIN [2] which significantly reduced the recurrence rates [3]. The second revolution was the application of laparoscopic surgery in the treatment of inguinal hernia during the early 1990 which led to decrease in postoperative pain and faster recovery along with low recurrence rates [4]. Today, a great competition is continuing between open and

laparoscopic mesh repairs. If majority of hernia repairs are still done with open techniques, laparoscopic hernia repair has gained popularity in North American and European countries [1]. A Canadian survey reported that one third of bilateral and recurrent hernias were repaired with this technique [5] and a German survey including 14 hospitals presented a 30% ratio for laparoscopic repair techniques [6]. This approach hadn't been described in our country. We report a case of a Transabdominal pre-peritoneal (TAPP) repair.

## OBSERVATION

A 57 years-old male patient was received in our unit for an intermittent non painful and reducible left groin swelling. He had no past history of surgery and didn't present signs of urinary obstruction. On physical examination, the swelling was above the inguinal ligament and the contralateral groin and rectal examination were normal. After patient' information and agreement, we decided to manage this inguinal hernia by a TAPP which is a laparoscopic trans-abdominal pre-peritoneal mesh plasty.

The pre-operative workshops were normal. The patient being imperatively ordered to evacuate his bladder just before being brought to the operating room. He was kept

in supine and under general anesthesia. We placed three trocars including one of 10mm in supra-umbilical, by “open-coelioscopy” and two workshops ports (supra-pubic and right iliac fossa) inserted under direct vision. The pneumoperitoneum was then created. The exploration of the cavity revealed a normal right inner inguinal ring. The table was placed in Trendelenburg and slightly turned toward the surgeon. The operating surgeon and the camera assistant stay on opposite side of the hernia. We realized a 4 cm peritoneal incision above the left inner inguinal ring (Figure 1). The indirect hernia sac was found (Figure 2A) and dissected for the vas deferens and spermatic vessels (Figure 2B). The sac, isolated, was then transected at the level of the inner inguinal ring. We extend the dissection to the pre-peritoneal fat resulting to a sufficient space to accommodate the mesh. The mesh was introduced through the optical port (Figure 3A). It was a polyester and polylactid mesh (10×15cm), pre-cut, slit, elliptic with a self-gripping overlapping flap. The mesh was placed into the created preperitoneal space with the slit around the spermatic cord and the overlapping flap beside the abdominal wall (Figure 3B). A thorough closure of the peritoneal incision was done (Figure 4) to prevent contact of viscera with the prosthetic mesh material. The operative time was 90 minutes.

Table 1: A classification of current repair techniques for inguinal hernias [1].

|  |
|--|
| <b>A. Tension-free prosthetic repairs</b>                |
| 1. Anterior repairs                                      |
| a. Lichtenstein repair and its modifications             |
| b. Plug repairs  |
| c. Patch and plug repairs                                |
| d. Double-layer devices                                  |
| 2. Posterior (preperitoneal) repairs                     |
| a. Open techniques via inguinal incision                 |
| b. Stoppa repair   |
| c. Laparoscopic/endoscopic repairs                       |
| i. Transabdominal preperitoneal (TAPP)                   |
| ii. Totally extraperitoneal (TEP)                        |
| <b>B. Tissue-Suture repairs</b>                          |
| 1. Bassini, Shouldice techniques and their modifications |
| 2. Marcy repair  |

## DISCUSSION

Even if some recent papers have reported that watchful waiting is a safe and acceptable option for minimally or asymptomatic hernias [7,8,9], traditionally almost all inguinal hernias are referred for surgical treatment following diagnosis. If numerous repair techniques are described in literature (Table 1), the European Hernia Society recommend (Grade A) with a level 1 of evidence that “all male adult (>30 years) patients with a symptomatic inguinal hernia should be operated using a mesh technique” [10]. When considering a non-mesh repair, the shouldice technique is the best one [10,11,12].

The (open) LICHENSTEIN and endoscopic inguinal hernia techniques are recommended as the best evidence-based options for the repair of primary unilateral hernia [10]. For the repair of recurrent hernias after conventional open repair, endoscopic inguinal hernia techniques are recommended [10]. When comparing open mesh (LICHENSTEIN) versus endoscopic mesh techniques, two meta-analysis published in 2005 [13,14] concluded that “they are significant advantages for endoscopy including lower incidence of wound infection, hematomas and chronic pain/numbness, with earlier return to normal activities or work (6 days)”.

There are two standardized techniques of laparoscopic groin hernia repair: Totally Extra-Peritoneal (TEP) and Trans-Abdominal Pre-Peritoneal (TAPP) repair. There is a paucity of published data with level 1 evidence comparing TAPP Vs TEP. With a level 3 evidence, the International EndoHernia Society state that “regarding overall complication rate, there is no obvious difference between TAPP and TEP. TAPP has a shorter operation and TEP is more suitable for regional anesthesia” [3]. Patients with contra-indications of general anesthesia aren’t eligible to a TAPP procedure. Since it is generally believed that TAPP is easier to teach and learn, we decided to start our experience in laparoscopic hernia repair by this technique.

The particularity of our own case is the trocars positioning. Usually in TAPP, the three trocars are placed at the umbilical level with the 2 working ports inserted at the external side of the rectus abdominus [3,15]. We prefer to insert one working port in supra-pubic and the other one in right iliac fossa for a left hernia (and in left iliac fossa for a left groin hernia). This positioning allow us to have a better triangulation between the port and the hernia site. Our mesh was self-gripping and didn’t require a fixation.

In developing countries, the shorter recovery time and shorter off work period after a laparoscopic hernia repair compensates the increased hospital cost compared to open repair [16]. We think that, the vulgarization of health insurance in our country could lead to the same result. Residents and surgeons should be aware of this technique. In our knowledge, this is the first report of a TAPP repair in our country.

## CONCLUSION

LICHENSTEIN and endoscopic inguinal hernia techniques are recommended as the best evidence options for hernias repair [10]. Concerning endoscopic techniques, TAPP is easier to teach and learn and there not seems to be a negative effect on outcome when operated by a resident versus an attending surgeon [10]. Endoscopic hernia repair training with adequate mentoring should then be started with junior residents.

## REFERENCES

- 1- KULACOGU H. Current options in inguinal hernia repair in adult patients. *HIPPOKRATIA*, 2011;15(3):223-231.
- 2- LICHENSTEIN IL, SHULMAN AG, AMID PK, MONTLLOR MM. The tension-free hernioplasty. *Am J Surg*, 1989;157:188-193.
- 3- BITTNER R, ARREGUI ME, BISGAARD T et al. Guidelines for laparoscopic (TAPP) and endoscopic (TEP) treatment of inguinal hernia [International Endohernia Society (IEHS)]. *Surg Endosc*, 2011;25:2773-2843.
- 4- DULUCQ JL. Traitement des hernies de l'aîne par la mise en place d'un patch prothétique par laparoscopie. Voie totalement extra-péritonéale. *Cah Chir*, 1991;79:15-16.
- 5- DESCOTEAUX JG, SUTHERLAND F. Inguinal hernia repair : a survey of canadian practice patterns. *Can J Surg*, 1999;42:127-132.
- 6- ZIESCHE M, MANGER T. Determining the status of laparoscopic surgery in East Brandenburg. Result of a survey. *Zentralbl Chir* 2000;125:997-1002.
- 7- TURAGA K, FITZGIBBONS RJ, PURI V. Inguinal hernias: should we repair? *Surg Clin North Am*, 2008;88:127-138.
- 8- BARKUN J, NEVILLE A, FITZGERALD GW, LITWIN D. Canadian Association of General Surgeon and American College of Surgeons. Evidence-based reviewed in surgery. Watchful waiting versus repair of inguinal hernia in minimally symptomatic men. *Can J Surg*, 2008;51:406-409.
- 9- FITZGIBBONS RJ Jr, GIOBBIE-HURDER A, GIBBS JO et al. Watchful waiting Vs repair of inguinal hernia in minimally symptomatic men: a randomized clinical trial. *JAMA*, 2006;295:285-292.
- 10- SIMONS MP, AUFENACKER T, BAY-NIELSEN M et al. European Hernia Society guidelines on the treatment of inguinal hernia in adult patients. *Hernia*, 2009;13:343-403.
- 11- AMATO B, MOJA L, PANICO S et al. Shouldice technique versus other open techniques for inguinal hernia repair. *Cochrane database Syst rev*, 2009;4:CD001543.
- 12- SIMONS MP, KLEIJNEN J, VAN GELDERE D et al. role of the shouldice technique in inguinal hernia repair: a systematic review of controlled trials and a meta-analysis. *Br J Surg*, 1996;83:734-738.
- 13- McCORMACK K, WAKE BL, FRASER C et al. Laparoscopic surgery for inguinal hernia repair: systematic review of effectiveness and economic evaluation. *Health Technol Assess*, 2005;9:1-203.
- 14- SCHMEDT CG, SAUERLAND F, BITTNER R. Comparison of endoscopic procedures Vs Lichenstein and other open mesh techniques for inguinal hernia repair: a meta-analysis of randomized controlled trials. *Surg Endosc*, 2005;19:188-199.
- 15- FROMONT G. Technique de hernioplastie par voie transabdomino-préperitonéale. EMC (Elsevier SAS, Paris), Techniques chirurgicales- Appareil digestif, 2006 : 40-127-B.
- 16- GREENBERG D, PEISER JG. Cost and benefits of laparoscopic inguinal hernia repair : is there an economic justification ? *Harefuah*, 2001;140:580-585.

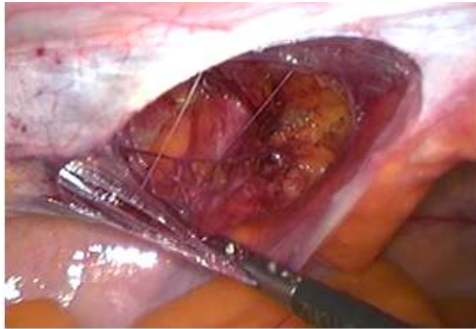


Fig 1:

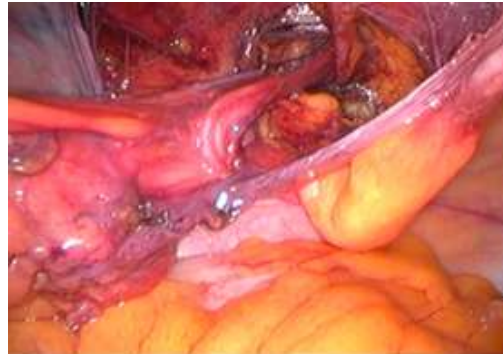


Fig 2A

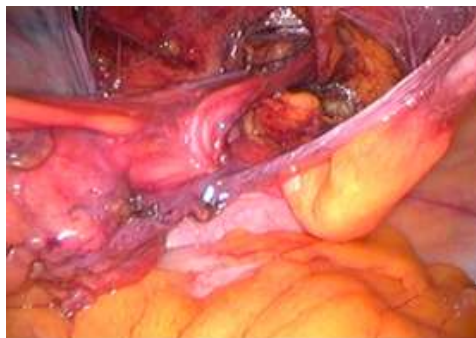

Fig 2B

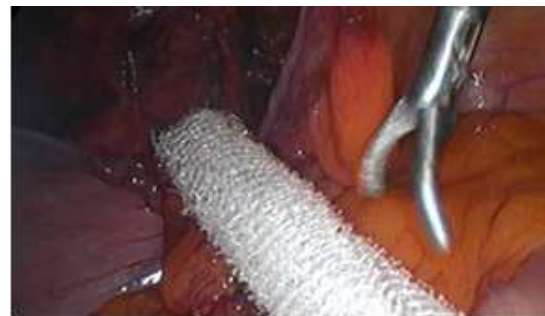

Fig 3A

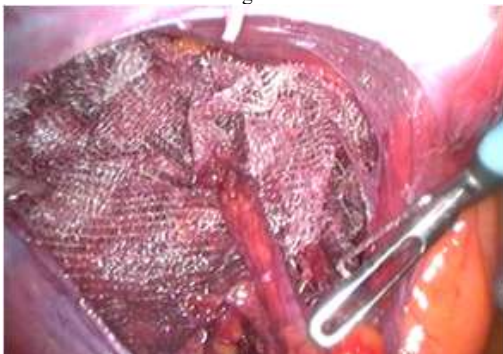


Fig 3B

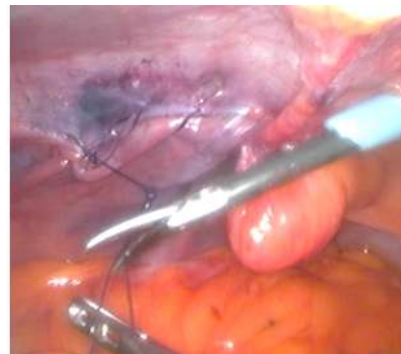

Fig 4